

# Wound Healing Activity of Silibinin in Mice

Rojalini Samanta, Ashok K. Pattnaik, Kishanta K. Pradhan, Beena K. Mehta, Shakti P. Pattanayak, Sugato Banerjee

Department of Pharmaceutical Sciences and Technology, Birla Institute of Technology, Ranchi, Jharkhand, India

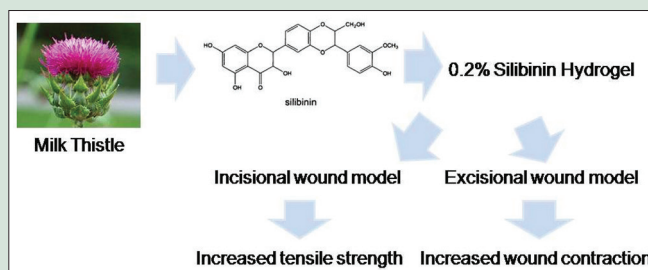
## ABSTRACT

**Background:** Silibinin is a semi-purified fraction of silymarin contained in milk thistle (*Silybum marianum Asteraceae*). Primarily known for its hepatoprotective actions, silymarin may also stimulate epithelialization and reduce inflammation in excision wound. Previous studies show antioxidant, anti-inflammatory, and antimicrobial actions of silibinin. However, wound healing property of silibinin is not well studied. **Objective:** This study investigates wound healing activity of silibinin topical formulation. **Materials and Methods:** Wound healing activity of 0.2% silibinin gel was assessed by incision and excision wound models in mice. Animals were divided into gel base, silibinin gel, and Mega Heal gel® treated groups with six animals in each group. Wound contraction, wound tissue tensile strength, and hydroxyproline content were measured, and histopathological evaluation of wound tissue of all the above treatment groups was carried out. **Results:** Application of 0.2% silibinin hydrogel for 8 days led to 56.3% wound contraction compared to 64.6% using standard Mega Heal gel with a subsequent increase in hydroxyproline content, which was significantly higher ( $P < 0.001$ ) over control animals showing 33.2% contraction. After 14 days, percentage of contraction reached 96.1%, 97.6%, and 86.7%, respectively. Wound tissue tensile strength with silibinin ( $223.55 \pm 3.82$  g) and standard ( $241.38 \pm 2.49$  g) was significantly higher ( $P < 0.001$ ) than control ( $174.06 \pm 5.75$  g). Histopathology of silibinin and standard gel treated wound tissue showed more fibroblasts, fewer macrophage infiltration, and well-formed collagen fibers. **Conclusion:** Here, we show potent wound healing activity of silibinin hydrogel formulation.

**Key words:** Excision wound, hydrogel, hydroxyproline, incision wound, silibinin

## SUMMARY

- 0.2% silibinin hydrogel showed potent wound healing activity in incision and excision wound models in mice.



**Abbreviations Used:** ROS: Reactive oxygen species

## Correspondence:

Dr. Sugato Banerjee,  
Department of Pharmaceutical Sciences  
and Technology, Birla Institute of Technology,  
Mesra, Ranchi - 835 215, Jharkhand, India.  
E-mail: sbanerjee@bitmesra.ac.in  
DOI : 10.4103/0974-8490.188880

Access this article online

Website: www.phcogres.com

Quick Response Code:



## INTRODUCTION

The use of herbal medicines worldwide has given an excellent opportunity for India to look for therapeutic lead compounds from our ancient systems of medicine including Ayurveda, which can be used for the development of new therapeutically active compounds. Over 50% of all modern drugs have a natural origin, and they play an important role in drug development programs.<sup>[1]</sup> Traditional milk thistle (*Silybum marianum Asteraceae*) extract primarily mentioned in ayurvedic texts as hepatoprotective consists of about 65–80% silymarin (a flavonolignan complex) and 20–35% fatty acids. Silymarin is a complex mixture of polyphenolic molecules including seven closely related flavonolignans (silybin A, silybin B, isosilybin A, isosilybin B, silychristin, isosilychristin, and silydianin) and one flavonoid (taxifolin).<sup>[2]</sup> Silibinin, a semi-purified fraction of silymarin, is primarily a mixture of two diastereoisomers, silybin A and silybin B, in a roughly 1:1 ratio.<sup>[3,4]</sup>

Wound is the physical injury that results in opening or breaking of the skin and proper method for the healing of wounds are essential for restoration of disrupted anatomical continuity and functional status of the skin.<sup>[5]</sup> Tissue repair and wound healing are a complex process that involves a series of biochemical and cellular reactions, beginning with inflammation and followed by reepithelialization, granulation tissue formation, and remodeling of the extracellular matrix.<sup>[6]</sup> During the inflammatory phase, macrophages mainly orchestrate the removal of fibrin and fibroblast proliferation. Wound healing proceeds only after

the inflammation stops.<sup>[7]</sup> Although the healing process progresses naturally, an infection can seriously delay this healing process by prolonging the inflammatory phase, disrupting the normal clotting mechanisms, promoting disordered leukocyte function, and ultimately delaying angiogenesis.<sup>[8]</sup> Antioxidants counter excess protease and reactive oxygen species (ROS), often formed by neutrophil accumulation in the wound site and protect from oxidative damage. Fibroblasts and other cells killed by excess ROS and antioxidants may protect from these adverse events.<sup>[9]</sup> Therefore, a variety of activities such as fibroblast growth stimulation, anti-inflammatory, antioxidant, and antimicrobial effects can explain the traditional use of plants for helping wounds to heal. For *in vivo* evaluation of wound healing activity, the use of the single model is inadequate since no single model adequately represents the various phases of healing. Hence, we chose two different *in vivo* models (excision and incision wound models) to assess the effect of silibinin on wound tissue.<sup>[10]</sup> Incision

This is an open access article distributed under the terms of the Creative Commons Attribution-NonCommercial-ShareAlike 3.0 License, which allows others to remix, tweak, and build upon the work non-commercially, as long as the author is credited and the new creations are licensed under the identical terms.

For reprints contact: reprints@medknow.com

Cite this article as: Samanta R, Pattnaik AK, Pradhan KK, Mehta BK, Pattanayak SP, Banerjee S. Wound healing activity of silibinin in mice. Phcog Res 2016;8:298-302.

wound models are more suitable for *in situ* techniques such as tensile strength, while excision wound models may provide enough material for determining biochemical and histological changes.<sup>[11]</sup> Silibinin has free radical scavenging property,<sup>[12-16]</sup> while it has also been shown to prevent inflammation by reducing, cytokines such as tumor necrosis factor- $\alpha$ , interleukin-1 $\beta$  levels in peripheral blood mononuclear cells *in vitro*.<sup>[17]</sup> It may also show anticancer activity.<sup>[18]</sup> Others have also shown antimicrobial actions of silibinin<sup>[19]</sup> and silibinin.<sup>[20]</sup> Silymarin may stimulate epithelialization and reduce inflammation in excision wound model in rats.<sup>[21]</sup> Silibinin (20%) organogel formulation on prolonged application has been shown to treat skin wounds in rats by increasing collagen content.<sup>[22]</sup> In the present study, we show potent wound healing activity of silibinin (0.2%) hydrogel which was comparable with Mega Heal gel<sup>®</sup> in mice.

## MATERIALS AND METHODS

### Animal care and handling

Swiss male albino mice weighing 25–30 g of either sex were used in the study. Animals were procured from Laboratory Animal House of Birla Institute of Technology, Mesra (Reg. no: 621/02/ac/CPCSEA). All animal experiments strictly complied with approval of the Institutional Animal Ethical Committee. The animals were kept in polyacrylic cages and maintained under standard housing conditions of temperature (24–27°C) and humidity (60–65%) with 12:12 light: Dark cycles. They were acclimatized for 7 days. The food was provided in the form of dry pellets (Amrut Diet, New Delhi, India) and water *ad libitum*.

### Gel preparation

Two mixtures were prepared: (a) 1 g carbopol 934 (Lubrizol CDH Chemicals, India) in distilled water with continuous agitation. (b) Methylparaben (0.5%; CDH Chemicals, New Delhi, India) in hot water and propylparaben (0.2%; CDH Chemicals, New Delhi, India) in propylene glycol (CDH Chemicals, New Delhi, India) were combined. The required quantity of silibinin mixed in distilled water with continuous stirring was added to mixture A, both the mixtures (a and b) were blended, and volume was made up to 100 mL. Triethanolamine (Sigma-Aldrich St. Lewis, MO, USA) was added dropwise to get neutral pH (6.8–7) and to obtain gel consistency, and then the prepared gel was packed in an airtight wide mouth container. Similar procedure was followed for the preparation of gel base.

### Skin irritation test

In the skin irritation study, either sex of mice was used. Animals were divided into four groups. Hair was depleted from the back of mice with the help of depilatories and area 4 cm<sup>2</sup> was marked on both sides. One side served as control and the other as test. The animals were used after 24 h.<sup>[23]</sup> After hair depletion, the gel was applied by spatula once daily for 7 days, and the site was covered with a cotton bandage and observed for sensitivity and the reaction as erythema and edema.

### Study design for wound healing activity

Incision and excision wound models were used to assess the wound healing profile of seed extract of *Silybum marianum* (silibinin; Sigma-Aldrich, St. Lewis, MO, USA) in mice ( $n = 6$ /group). The drug treatments were as follows:

- Group A: Received gel base and served as normal controls
- Group B: Received reference standard (Mega Heal gel<sup>®</sup>; Aristo Pharmaceuticals Ltd., Mumbai, India)
- Group C: Received silibinin gel (0.2% w/w).

### Evaluation of wound healing activity

Wound healing activity was assessed by incision and excision wound healing models. All woundings were carried under ether anesthesia. Wounds were treated immediately after wound creation.

#### Incision wound model

Mice in each group were anesthetized, and two paravertebral-long incisions of approximately 1.5 cm were made through the skin and cutaneous muscles at a distance of about 1.0 cm from the midline on each side of the depilated back of the mice. No local or systemic antimicrobials were used throughout the experiment. After the incision was made, the parted skin was kept together and stitched with black silk thread at 0.5 cm interval. The wound was left undressed. Gel base, silibinin, and standard gel were administered once daily for 9 days at 11 a.m. to respective group of animals.

#### Evaluation of tensile strength

On day 10 when the wound has healed, sutures were removed under ether anesthesia. A small region of wound was cut so that the incision lies exactly in the middle of the previous wound area. Four small curved needles (No: 14) were pierced through the skin, two on either side. Two needles of one side were tied to a rod, whereas the other two needles were tied to a freely hanging plastic bottle. Slowly water was added to the bottle until the wound began to open. The amount of water in the bottle was weighed and considered as an indirect measure of wound tensile strength. The mean tensile strength of the paravertebral incisions on both sides of the animal was taken as the measures of the tensile strength of the wound for an individual animal. The tensile strength of silibinin and standard gel treated wounds was compared with gel base-treated control.<sup>[24]</sup>

#### Excision wound model

The mice were anesthetized with diethyl ether. After anesthesia, hair was removed by shaving the dorsal back of the mice. Ethanol (70%) was used as antiseptic for the shaved region before making the wound. Excision wound was made by removing a full thickness of the skin of 7 mm<sup>2</sup> circular area from a predetermined shaved area on the back of each animal. The wound was left undressed, and no local or systemic antimicrobial agent was used. Each mouse was placed in a separate cage.

#### Determination of wound contraction

After wound creation, experimental animals were divided into three groups as described earlier each group consisting of six animals. After surgery, the excision wound margins were traced by the changes in wound area planimetrically. The size of wounds was traced on a transparent paper every alternate day throughout the monitoring period; measurements were continued up to 14 days. From the tracings, wound surface area was evaluated.<sup>[10]</sup>

Percentage of wound contraction was determined using the following formula:

$$\text{Percent wound contraction} = (\text{healed area}/\text{total area}) \times 100.$$

### Histopathological evaluation

Excision wound model was used for histopathological evaluation. After deep ether anesthesia, a cross-section of full thickness skin (wound tissue) specimen from each group ( $n=3$ , standard gel, silibinin gel, or gel base-treated) was taken on day 10 of the experiment for histopathological evaluation. The tissue was cut into 5–10  $\mu\text{m}$  sections using microtome and stained with hematoxylin and eosin. Stained tissue slides were examined under the Leica DME microscope (Leica Microsystems, Germany) ( $\times 40$  objective). Photographs were captured using 7.1 M Pixel Canon PowerShot (Canon, India).

## Estimation of hydroxyproline content

Hydroxyproline content was analyzed for 8-day postinjury granulation tissue. The hydrolyzed samples of wound tissue (30 mg) were mixed with 1 mL of 0.01 M CuSO<sub>4</sub> followed by the addition of 1 mL of 2.5 N NaOH and 1 mL of 6% H<sub>2</sub>O<sub>2</sub>. The solution was mixed and shaken occasionally for 5 min. All the tubes (con, test and standard) were incubated at 80°C for 5 min with frequent vigorous shaking. Upon cooling, 4 mL of 3N H<sub>2</sub>SO<sub>4</sub> was added with constant agitation. Finally, 2 mL of 5% p dimethylaminobenzaldehyde was added and incubated at 70°C for 15 min and cooled in a water bath to 20°C. Absorbance was measured at 500 nm using a UV-VIS spectrophotometer (CE7200, Cecil Instruments Ltd., Cambridge, USA). Hydroxyproline content in the samples was calculated from standard hydroxyproline calibration curve.<sup>[25]</sup>

## Statistical analysis

The data were analyzed using one-way analysis of variance followed by Tukey's *post hoc* test using GraphPad Prism 4.0 (San Diego, California, USA). The data were expressed as a mean ± standard error of mean.  $P < 0.05$  was considered statistically significant.

## RESULTS

### General characteristics

The 0.2% silibinin gel was white clear and transparent, smooth in texture, pH was 6.8 with good spreadability (12 g/cm/s), homogeneous, and adhered suitably to the imperative surface. The formulated topical gel was nonirritant upon application.

### Skin irritation test

In the skin irritation, tested hydrogel concentrations did not show any symptoms of irritation and inflammation

### Tensile strength for incision wound model

In incision wound model, the incision wounds treated with 0.2% silibinin gel for 9 days showed a significant increase in tensile strength ( $223.55 \pm 3.82$  g;  $P < 0.01$ ) as compared to gel base-treated control animals ( $174.06 \pm 5.75$  g), whereas standard (colloidal silver gel; Mega Heal) formulation also showed a significantly higher ( $241.38 \pm 2.49$  g  $P < 0.001$ ) tensile strength compared to control. The tensile strength of standard gel and 0.2% silibinin gel was comparable ( $P > 0.05$ ) [Table 1].

### Wound contraction for excision wound model

Excision wound model showed that all silibinin and standard gel-treated animals exhibited a significant increase in the percentage of wound contraction as compared to control groups over the period of 14 days ( $P < 0.01$ ). Application of 0.2% silibinin gel for 8 days led to 56.3% wound contraction compared to 64.6% using standard, whereas control animals showed 33.2% contraction. After 14 days, both standard and silibinin treatment led to nearly complete healing of the wound (96.1% and 97.6%, respectively), whereas gel base-treated animals showed significantly less ( $P < 0.01$ ) 86.7% healing [Table 2]. Photographs showing wound contraction through days 2–14 [Figure 1].

### Histopathological evaluation

Hematoxylin- and eosin-stained sections of granulation tissue collected on day 10 after 9 days of silibinin gel, Mega Heal gel, or gel base-treated groups were examined for collagen synthesis macrophage infiltration, fibroblasts, and new blood vessel formation. The images revealed that animals treated with 0.2% silibinin showed more fibroblasts, less infiltrating of macrophages, and well-formed collagen fibers [Figure 2].

## Hydroxyproline content

Hydroxyproline content in silibinin ( $168.3 \pm 7.2$ ) and Mega Heal gel ( $185.3 \pm 24.2$ ) treated groups were significantly higher ( $P < 0.001$ ) compared to gel base-treated control ( $66.7 \pm 8.5$ ) animals [Figure 3].

## DISCUSSION

Proper healing of the wound is essential for restoration of disrupted anatomical continuity and disturbed functional status of skin.<sup>[26]</sup> Wound

**Table 1:** Evaluation of tensile strength by 0.2% silibinin for incision wound in rats

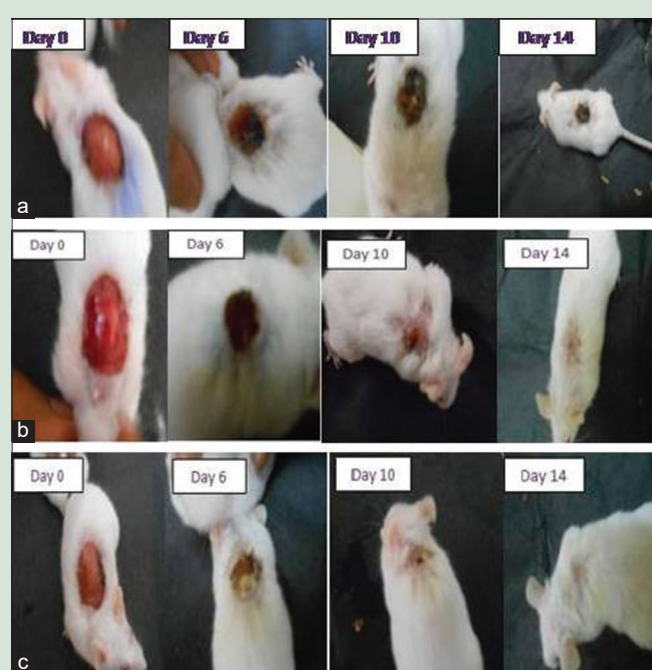
Number of animals	Treatment	Tensile strength (g) (mean±SEM)
6	Control (gel base)	174.06±5.75
6	Standard (Mega Heal gel)	241.38±2.49***
6	Silibinin (0.2% gel)	223.55±3.82**

Each value is the mean±SEM,  $n=6$ , \*\* $P < 0.01$  silibinin versus control, \*\*\* $P < 0.001$  standard versus control,  $P > 0.05$  silibinin versus standard. SEM: Standard error of mean

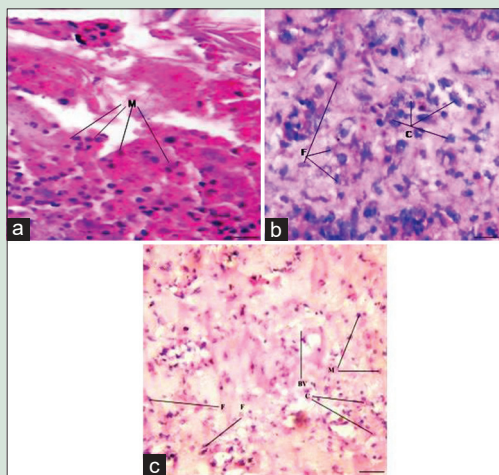
**Table 2:** Evaluation of wound contraction by 0.2% silibinin for excision wound in rats

Postwounding days	Percentage wound contraction (mean±SEM)		
	Control (gel base)	Standard (Mega Heal gel)	Silibinin (0.2% gel)
2	4.55±1.26	5.55±1.09	5.25±1.98
4	16.2±0.48	12.87±3.96	13.7±3.65
6	29.7±1.00	50.37±1.32**	39.62±2.21***
8	33.17±1.15	64.6±1.27***	56.32±1.6***
10	61.07±1.04	80.35±1.64***	70.95±1.51***
12	76.07±0.83	95.28±1.49***	94.1±1.56***
14	86.75±0.85	97.60±1.08**	96.15±0.86**

Each value is the mean±SEM,  $n=6$ , standard versus control \*\* $P < 0.01$  on day 6 and 14, whereas \*\*\* $P < 0.001$  on days 8, 10, and 12. Silibinin versus control \*\*\* $P < 0.001$  on days 6–12 and \*\* $P < 0.01$  on day 14. SEM: Standard error of mean



**Figure 1:** Effect of silibinin on wound healing. Pictorial representation of wound contraction in (a) gel base-treated (b) Mega Heal gel-treated and (c) 0.2% silibinin-treated Swiss albino mice at days 0–14

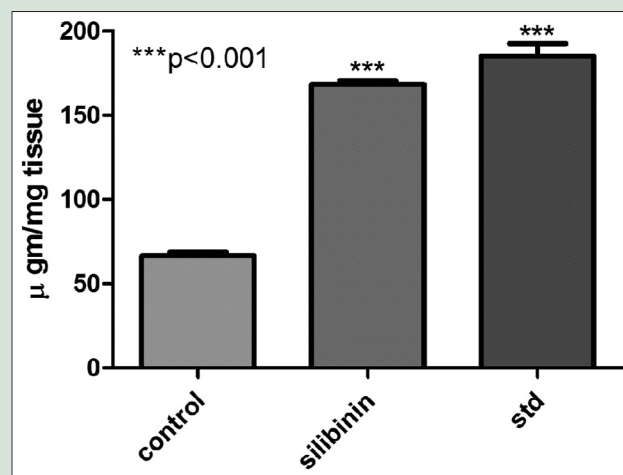


**Figure 2:** Microscopic view of healing wound granulation tissue and remodeling epidermis/dermis in (a) gel base-treated (b) 0.2% silibinin-treated (c) Std (Mega Heal gel) treated (9 days) animal groups. Sections show representative images for H and E stained epidermis and dermis under  $\times 40$  objective. Arrows pointing the events of wound healing BV: Blood vessels, C: Collagen, F: Fibroblast, and M: Mononuclear cells. Scale bar represents  $100 \mu\text{m}$

healing is a sequential process, which consists of different phases such as hemostasis, inflammation, proliferation, and remodeling.<sup>[27]</sup> The proliferative phase constitutes angiogenesis, collagen deposition, granulation, epithelialization, and wound contraction.<sup>[28]</sup>

Free radicals may potentiate wound formation while free radical scavenging has been associated with wound healing potential.<sup>[29]</sup> The free radical scavenging properties of *S. marianum* have been attributed to its flavonoids which may act as antioxidants.<sup>[30]</sup> Flavonoids are responsible for the free radical scavenging activity and are known to promote the wound healing process which is responsible for wound contraction and increased rate of epithelialization.<sup>[31]</sup> Previous works, as well as preliminary studies in our laboratory show antioxidant property of silibinin.<sup>[32]</sup> Wounds are usually accompanied by pain as well as reddening and edema of the surrounding tissues. These are all classical symptoms of inflammation.<sup>[33]</sup> There are reports suggesting the anti-inflammatory potential of silibinin which was confirmed by our preliminary studies.<sup>[17]</sup> Here, we used two different *in vivo* models (excision and incision wound models) to assess the effect of silibinin on wound tissue.

Collagen deposition, granulation, epithelialization, and wound contraction are characteristics of proliferative phase of wound healing. Epithelial cells crawl across the wound bed to cover it, and myofibroblasts help it contract.<sup>[34]</sup> Wound contraction occurs throughout the healing process. Topical application of 0.2% silibinin showed an increase in the percentage of wound contraction as compared to control in excision wound model. Significant wound contraction and complete healing by 14<sup>th</sup> day indicated rapid epithelialization and collagenization [Table 2]. The increase in tensile strength of wound tissue represents effective healing. It is an indicator of collagen synthesis and collagen maturation.<sup>[10]</sup> Collagen plays a central role in the healing of wounds, and it is a principal component of connective tissue which provides the structural framework for regenerating tissues. Collagen is made up of amino acid, hydroxyproline, the major component of extracellular matrix thus rendering strength and support to the tissue. Breakdown of collagen liberates free hydroxyproline and its peptides. Thus, hydroxyproline levels correlate well with the amount of tissue collagen and is an established indicator for tissue collagen turnover.<sup>[33]</sup>



**Figure 3:** Effect of silibinin on hydroxyproline content. Both 0.2% silibinin and Std (Mega Heal gel) showed a significant increase in hydroxyproline content compared to gel base-treated control animals. Each value represents mean  $\pm$  standard error of mean,  $n = 6$

Here, 0.2% silibinin gel led to significant increase in hydroxyproline levels in wound tissue compared to control thus suggesting increase in collagen content upon treatment. In the incision model, 0.2% silibinin showed a significant increase in tensile strength as compared to control. Hence, we postulate 0.2% silibinin to increase the rate of collagen synthesis leading to increased tensile strength in wound tissue, helping the process of healing. Enhanced healing activity has been attributed to increased collagen synthesis and angiogenesis. This improves circulation, thus providing oxygen and nutrients, essential for the healing process of the wound site.<sup>[35]</sup> Rate of wound contraction may also be attributed to increased proliferation of fibroblasts and their subsequent transformation to myofibroblasts. Enhanced contractile property of myofibroblast may result in the shorter epithelialization period thus helping the wound heal faster.<sup>[23]</sup> Histopathological study of granulation tissue in 0.2% silibinin gel-treated wound showed more collagen fibers, fibroblasts, and proliferating blood capillaries (angiogenesis) compared to gel base-treated wound. This led to increased tensile strength in the wound tissue, resulting in effective wound healing.

## CONCLUSION

In the current study, we show potent wound healing potential of 0.2% silibinin hydrogel in mice.

## Acknowledgment

The authors would like to acknowledge the Department of Pharmaceutical Sciences and Technology, Birla Institute of Technology, Mesra, Ranchi, India, for providing the necessary facilities to carry out the study.

## Financial support and sponsorship

Nil.

## Conflicts of interest

There are no conflicts of interest.

## REFERENCES

- Newman DJ, Cragg GM. Natural products as sources of new drugs over the 30 years from 1981 to 2010. *J Nat Prod* 2012;75:311-35.

2. Kroll DJ, Shaw HS, Oberlies NH. Milk thistle nomenclature: Why it matters in cancer research and pharmacokinetic studies. *Integr Cancer Ther* 2007;6:110-9.
3. Rainone F. Milk thistle. *Am Fam Physician* 2005;72:1285-8.
4. Hogan FS, Krishnegowda NK, Mikhailova M, Kahlenberg MS. Flavonoid, silibinin, inhibits proliferation and promotes cell-cycle arrest of human colon cancer. *J Surg Res* 2007;143:58-65.
5. Strodtbeck F. Physiology of wound healing. *Nurs Rev* 2001;1:43-5.
6. Ponrasu T, Madhukumar KN, Ganeshkumar M, Iyappan K, Sangeethapriya V, Gayathri VS, *et al.* Efficacy of *Acorus calamus* on collagen maturation on full thickness cutaneous wounds in rats. *Pharmacogn Mag* 2014;10 Suppl 2:S299-305.
7. Baillie JK, Thompson AA, Irving JB, Bates MG, Sutherland AI, Macnee W, *et al.* Oral antioxidant supplementation does not prevent acute mountain sickness: Double blind, randomized placebo-controlled trial. *QJM* 2009;102:341-8.
8. Diegelmann RF, Evans MC. Wound healing: An overview of acute, fibrotic and delayed healing. *Front Biosci* 2004;9:283-9.
9. Jha P, Flather M, Lonn E, Farkouh M, Yusuf S. The antioxidant vitamins and cardiovascular disease. A critical review of epidemiologic and clinical trial data. *Ann Intern Med* 1995;123:860-72.
10. Thakur R, Jain N, Pathak R, Sandhu SS. Practices in wound healing studies of plants. *Evid Based Complement Alternat Med* 2011;2011:438056.
11. Barreto RS, Albuquerque-Júnior RL, Araújo AA, Almeida JR, Santos MR, Barreto AS, *et al.* A systematic review of the wound-healing effects of monoterpenes and iridoid derivatives. *Molecules* 2014;19:846-62.
12. Basaga H, Poli G, Tekkaya C, Aras I. Free radical scavenging and antioxidative properties of "silibin" complexes on microsomal lipid peroxidation. *Cell Biochem Funct* 1997;15:27-33.
13. van Wenum E, Jurczakowski R, Litwinienko G. Media effects on the mechanism of antioxidant action of silybin and 2,3-dehydrosilybin: Role of the enol group. *J Org Chem* 2013;78:9102-12.
14. Haddad Y, Vallerand D, Brault A, Haddad PS. Antioxidant and hepatoprotective effects of silibinin in a rat model of nonalcoholic steatohepatitis. *Evid Based Complement Alternat Med* 2009;201:10-20.
15. Marouf BH, Zalzal MH, Al-Khalifa II, Aziz TA, Hussain SA. Free radical scavenging activity of silibinin in nitrite-induced hemoglobin oxidation and membrane fragility models. *Saudi Pharm J* 2011;19:177-83.
16. Wang Q, Zou L, Liu W, Hao W, Tashiro S, Onodera S, *et al.* Inhibiting NF- $\kappa$ B activation and ROS production are involved in the mechanism of silibinin's protection against D-galactose-induced senescence. *Pharmacol Biochem Behav* 2011;98:140-9.
17. Giorgi VS, Peracoli MT, Peracoli JC, Witkin SS, Bannwart-Castro CF. Silibinin modulates the NF- $\kappa$ B pathway and pro-inflammatory cytokine production by mononuclear cells from preeclamptic women. *J Reprod Immunol* 2012;95:67-72.
18. Tyagi A, Agarwal C, Harrison G, Glode LM, Agarwal R. Silibinin causes cell cycle arrest and apoptosis in human bladder transitional cell carcinoma cells by regulating CDKI-CDK-cyclin cascade, and caspase 3 and PARP cleavages. *Carcinogenesis* 2004;25:1711-20.
19. Lee DG, Kim HK, Park Y, Park SC, Woo ER, Jeong HG, *et al.* Gram-positive bacteria specific properties of silybin derived from *Silybum marianum*. *Arch Pharm Res* 2003;26:597-600.
20. Lee YS, Jang KA, Cha JD. Synergistic antibacterial effect between silibinin and antibiotics in oral bacteria. *J Biomed Biotechnol* 2012;2012:618081.
21. Sharifi R, Rastegar H, Kamalinejad M, Dehpour AR, Tavangar SM, Paknejad M, *et al.* Effect of topical application of silymarin (*Silybum marianum*) on excision wound healing in albino rats. *Acta Med Iran* 2012;50:583-8.
22. Tabandeh MR, Oryan A, Mohammad-Alipour A, Tabatabaei-Naieni A. Silibinin regulates matrix metalloproteinase 3 (stromelysin1) gene expression, hexoseamines and collagen production during rat skin wound healing. *Phytother Res* 2013;27:1149-53.
23. Kulkarni SK, Jain NK. Pharmacological and pharmacokinetic studies on marketed gel formulation of nimesulide. *J Indian Drugs* 2001;38:63-6.
24. Mehta BK, Pattnaik AK. Enhancement and validation of wound healing activity with herbal gel formulated from sub-fraction of *Buchanania lanzan* spreng. bark extract. *Int J Pharm Pharm Sci* 2014;6:281-6.
25. Upadhyay A, Chattopadhyay P, Goyary D, Mazumder PM, Veer V. Euphorbia hirta accelerates fibroblast proliferation and Smad-mediated collagen production in rat excision wound. *Pharmacogn Mag* 2014;10 Suppl 3:S534-42.
26. Umachigi SP, Kumar GS, Jayaveera K, Kishore KD, Ashok KC, Dhanapal R. Antimicrobial, wound healing and antioxidant activities of *Anthocephalus cadamba*. *Afr J Tradit Complement Altern Med* 2007;4:481-7.
27. Guo S, Dipietro LA. Factors affecting wound healing. *J Dent Res* 2010;89:219-29.
28. Singhal A, Gupta H, Bhati V. Wound healing activity of *Argyrea nervosa* leaves extract. *Int J Appl Basic Med Res* 2011;1:36-9.
29. Lai HY, Lim YY, Kim KH. Potential dermal wound healing agent in *Blechnum orientale* Linn. *BMC Complement Altern Med* 2011;11:62.
30. Kumar S, Pandey AK. Chemistry and biological activities of flavonoids: An overview. *Sci World J* 2013:1-16.
31. Pavithra PS, Sreevidya N, Verma RS. Antibacterial and antioxidant activity of methanol extract of *Evolvulus nummularius*. *Indian J Pharmacol* 2009;41:233-6.
32. Naso LG, Ferrer EG, Butenko N, Cavaco I, Lezama L, Rojo T, *et al.* Antioxidant, DNA cleavage, and cellular effects of silibinin and a new oxovanadium (IV)/silibinin complex. *J Biol Inorg Chem* 2011;16:653-68.
33. Song HS, Park TW, Sohn UD, Shin YK, Choi BC, Kim CJ, *et al.* The effect of caffeic acid on wound healing in skin-incised mice. *Korean J Physiol Pharmacol* 2008;12:343-7.
34. Nayak BS, Ramlogan S, Chalapathi Rao A, Maharaj S. *Neurolaena lobata* L. promotes wound healing in Sprague Dawley rats. *Int J Appl Basic Med Res* 2014;4:106-10.
35. Szabo S, Kusstatscher S, Sakoulas G, Sandor Z, Vincze A, Jadus M. Growth factors: New "endogenous drugs" for ulcer healing. *Scand J Gastroenterol Suppl* 1995;210:15-8.

### ABOUT AUTHOR



Sugato Banerjee

**Dr. Sugato Banerjee**, is Assistant Professor at Department of Pharmaceutical Sciences and Technology, BIT, Mesra, Ranchi. His research interests include pharmacological screening of natural products based on ethnomedical usage.