

## Anti-*Leishmania* Activity of Osthole

Elahesh Kordzadeh Kermani<sup>1</sup>, Seyed Ebrahim Sajjadi<sup>1</sup>, Seyed Hossein Hejazi<sup>2</sup>, Reza Arjmand<sup>3</sup>, Sedigheh Saberi<sup>2</sup>, Abbas Ali Eskandarian<sup>2</sup>

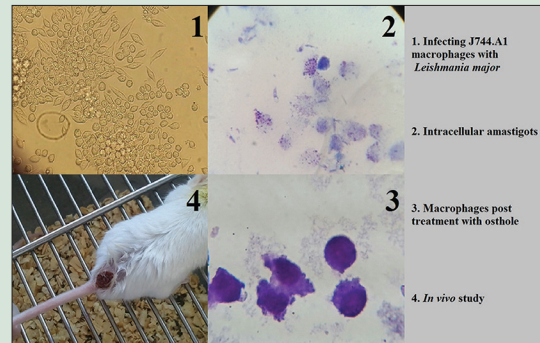
<sup>1</sup>Department of Pharmacognosy, School of Pharmacy and Pharmaceutical Sciences, Isfahan University of Medical Sciences, Isfahan, <sup>2</sup>Department of Medical Parasitology and Mycology, School of Medicine, Isfahan University of Medical Sciences, Isfahan, <sup>3</sup>Department of Medical Parasitology, School of Medicine, Ahvaz Jundishapur University of Medical Sciences, Ahvaz, Iran

### ABSTRACT

**Background:** Treatment of cutaneous leishmaniasis (CL) is occasionally highly resistant to pentavalent antimonials, the gold standard in pharmacotherapy of CL. Since there is no effective vaccine, the discovery of natural antileishmanial products as complementary therapeutic agents could be used to improve the current regimens. **Objective:** In this study *in vitro* and *in vivo* antileishmanial activities of osthole, a natural coumarin known to possess antibacterial and parasitocidal activities are evaluated. **Materials and Methods:** *Leishmania major* infected J774.A1 macrophages were treated with increasing concentrations of osthole. CL lesions of BALB/c mice were treated topically with 0.2% osthole. **Results:** Osthole exhibited dose-dependent leishmanicidal activity against intracellular amastigotes with IC<sub>50</sub> value of 14.95 µg/ml. Treatment of CL lesions in BALB/c mice with osthole significantly declined lesion progression compared to untreated mice ( $P < 0.05$ ), however did not result in recovery. **Conclusion:** Osthole demonstrated remarkable leishmanicidal activity *in vitro*. Higher concentrations of osthole may demonstrate the therapeutic property *in vivo*. **Key words:** Cutaneous leishmaniasis, *Leishmania major*, Leishmanicidal, Osthole

### SUMMARY

- In vitro* and *in vivo* antileishmanial activities of osthole, a pernylated coumarin extracted from *Prangos asperula* Boiss., are studied against *Leishmania major*.



Access this article online

Website: [www.phcogres.com](http://www.phcogres.com)

Quick Response Code:



### Correspondence:

Dr. Elahesh Kordzadeh Kermani,  
School of Pharmacy and Pharmaceutical  
Sciences, Isfahan University of Medical Sciences,  
Hezar Jerib Avenue, Isfahan, Iran, 73461-81746.  
E-mail: [kordzadeh.elahesh@gmail.com](mailto:kordzadeh.elahesh@gmail.com)  
DOI: 10.4103/0974-8490.178650

## INTRODUCTION

Leishmaniasis is a poverty-associated disease with diverse clinical manifestations caused by several species of protozoan parasites of the genus *Leishmania*. According to the World Health Organization epidemiological report, tegumentary leishmaniasis (cutaneous leishmaniasis [CL] and mucocutaneous leishmaniasis) appears around 1.5 million cases per annum in 82 countries;<sup>[1]</sup> and exhibits dermatological symptoms in exposed parts of the skin leaving permanent deformative scars. Parasitocidal pentavalent antimonial compound (meglumine antimoniate, Glucantime<sup>®</sup>) remains the first-line medication in pharmacotherapy of CL with limitations such as toxicity, low tolerability due to painful parenteral administration, and inefficacy against resistant species.<sup>[2]</sup> Since there is no effective vaccine, improvement of the current regimens could be used to control CL.<sup>[3]</sup> Hence, the discovery of natural products with anti-*Leishmania* activity as complementary therapeutic agents is of high importance.<sup>[4]</sup>

Osthole (Osthol) a natural coumarin known as a component of Traditional Chinese Medicine has received considerable interest as a result of its various pharmacological activities. Osthole is reported to occur in a number of plants native to China, Mediterranean, and some *Prangos* spp. found in the Middle-East.<sup>[5-7]</sup> *Prangos* species have been traditionally used as antihelmintic, antifungal, and antibacterial remedies in the Middle-East and Mediterranean regions.<sup>[8,9]</sup>

Pharmacological activities of osthole are being markedly under investigation, provoking it a promising natural lead compound for novel drug discovery.<sup>[10]</sup> Osthole is reported to possess parasitocidal activities

against *Trichomonas vaginalis*, a protozoan parasite<sup>[11]</sup> and *Dactylogyrus intermedius*, a helminth parasite.<sup>[12]</sup>

The aim of this study is to evaluate antileishmanial activities of osthole, extracted from *Prangos asperula* Boiss, *in vitro* using *Leishmania major* infected murine macrophage model and therapeutic property *in vivo* using infected BALB/c mice.

## MATERIALS AND METHODS

### Extraction and purification of osthole from *Prangos asperula* Boiss.

*P. asperula* Boiss. was collected in April - June 2013 from Dena mountains, environs of Yasouj (West of Iran), at an altitude of 2500 m above the sea level. The plant was identified by Azizollah Jafari, Department of Botany, Yasouj University. Osthole was isolated via *n*-hexane soxhlet extraction of 100 g air dried fruits. The extract was cooled at 4–5°C following evaporation of the solvent to form a semi pure yellow mass,

This is an open access article distributed under the terms of the Creative Commons Attribution-NonCommercial-ShareAlike 3.0 License, which allows others to remix, tweak, and build upon the work non-commercially, as long as the author is credited and the new creations are licensed under the identical terms.

For reprints contact: [reprints@medknow.com](mailto:reprints@medknow.com)

Cite this article as: Kermani EK, Sajjadi SE, Hejazi SH, Arjmand R, Saberi S, Eskandarian AA. Anti-*Leishmania* activity of osthole. Phcog Res 2016;8:S1-4.

later washed with chilled *n*-hexane for several times to enhance the purification. Eventually, the sample was recrystallized until pure osthole crystalline was formed.<sup>[13]</sup> A voucher specimen of the plant is retained at the herbarium of Department of Pharmacognosy, School of Pharmacy, Isfahan University of Medical Sciences, Iran (1126).

### Parasite culture

*L. major* (MRHO/IR/75/ER) has been isolated from the previously infected BALB/c mice spleens and kept cryopreserved at  $-80^{\circ}\text{C}$ . The promastigotes were warmed up to  $25^{\circ}\text{C}$  and incubated for 3–5 days in N.N.N medium; subsequently, passaged at  $25^{\circ}\text{C}$  in RPMI 1640 medium (PAA, Australia), supplemented with 10% inactivated fetal bovine serum (Sigma-Aldrich, US), 100 U/ml penicillin, and 100  $\mu\text{g}/\text{ml}$  streptomycin.<sup>[14]</sup>

### Macrophage culture

Murine macrophage cell lines (J774 A.1) were purchased from Pasteur Institute, Tehran, Iran. The cryopreserved cell lines were melted, immediately washed with phosphate-buffered saline (PBS), and cultured in RPMI 1640 supplemented with 20% fetal bovine serum and 100  $\mu\text{g}/\text{ml}$  streptomycin, subsequently, incubated in 5%  $\text{CO}_2$  at  $37^{\circ}\text{C}$ . By the time the macrophages developed pseudopodia and adhered to the bottom of the plates, they were harvested utilizing a cell scraper and washed by PBS (centrifuged at 1500 rpm for 5 min), and seeded in to 6 well culture plates at concentration of  $2 \times 10^6$  macrophages/well.<sup>[15]</sup>

### Evaluation of anti-amastigote activity

Promastigotes in the stationary phase of growth were centrifuged 3000 rpm for 10 min at room temperature, then resuspended and washed with medium. To infect the macrophages, parasites at the ratio of seven promastigotes per macrophage were introduced to the cultures in which the fresh medium had been replaced previously. The infected cultures were incubated at  $33^{\circ}\text{C}$  for 6 h, and to complete the phagocytosis process at  $37^{\circ}\text{C}$  for 24 h. Subsequently, they were washed with medium to remove the unphagocytosed parasites. Each well was daily observed using an invert microscope to determine the number of amastigotes and intensity of the infection. By the time 80% of the macrophages were infected, osthole with serial concentrations (5–50  $\mu\text{g}/\text{ml}$ ) was added (osthole was dissolved in dimethyl sulfoxide [DMSO] and diluted by complete medium). DMSO treated and untreated infected macrophages were used as negative controls and 100  $\mu\text{g}/\text{ml}$  meglumine antimoniate, MA-treated (Glucantime<sup>®</sup>, Aventis, France) infected macrophages was used as positive control.

The cells were fixed with methanol and stained with Giemsa 12, 24, 48, and 72 h posttreatment. Anti-amastigote activity was evaluated by numeration of the amastigotes in 100 macrophages. Each assay was performed in triplicate. The  $\text{IC}_{50}$  value was determined using a logarithmic dose – response regression curve.<sup>[16]</sup>

### Animals

The *in vivo* procedures of this experimental study were in compliance with guidelines of Isfahan University of Medical Sciences (Isfahan, Iran) to keep and use the laboratory animals in accordance with the Animal Ethics Committee.

The animals used in this research provided by the Center for Research and Training in Skin Diseases and Leprosy, Tehran, Iran, were 6–8 week-old-mice,  $20 \pm 5$  g weight female BALB/c type.

The animals were housed in standard cages with access to water and standard food at  $21^{\circ}\text{C} \pm 2^{\circ}\text{C}$ , and 40–50% humidity conditions in a colony room under 12:12 h light/dark cycle.<sup>[17]</sup>

### Infecting BALB/c mice by injection of *Leishmania major*

CL lesions were induced at the base of tail via subcutaneous injection of  $10^7$  viable promastigotes in 0.1 ml PBS.<sup>[18]</sup>

### Treatment of infected animals

Four weeks later when CL lesions were developed, mice with mean lesion size  $\approx 2.3 \pm 0.2$  mm were selected and divided into four groups of eight (A, B, C, and D). Mice of group (A) were treated topically with 0.2% osthole<sup>[19]</sup> (osthole dissolved in 1 ml DMSO diluted by xanthan gel up to 10 ml), group (B) received 100 mg/kg Glucantime<sup>®</sup> intralesionally, and group (C) was treated with 10% (v/v) DMSO-xanthan gel. The treatment was performed daily for 14 consecutive days, and mice of group (D) were left untreated.<sup>[19]</sup>

### Measurement of lesion size

Before, during, and 14 days after the treatment period the horizontal and vertical diameters (mm) of lesions were measured using calipers every 4 days. Mean lesion size in each animal was determined according to the formula  $S = (D + d)/2$ .<sup>[17]</sup>

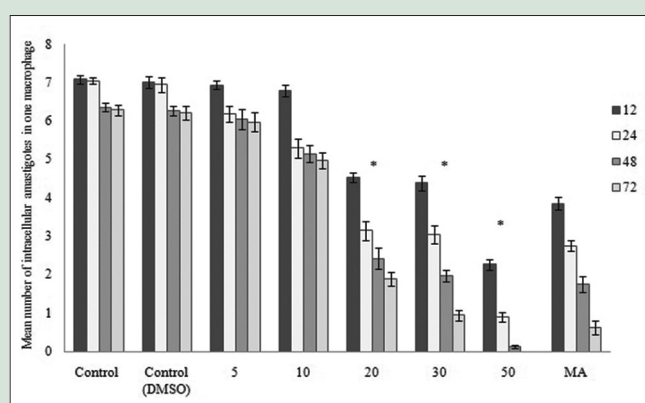
### Statistical analysis

In this study, all the results are represented in means  $\pm$  standard deviation. The statistical data analysis was done utilizing independent samples *t*-test for the *in vitro* study and paired samples *t*-test for the *in vivo* study.  $P < 0.05$  is considered statistically significant.

## RESULTS

### *In vitro* study

The results obtained from numeration of intracellular amastigotes demonstrated that osthole decreased the viability of amastigotes in J774.A1 macrophages in a dose-dependent manner with  $\text{IC}_{50}$  value of 14.95  $\mu\text{g}/\text{ml}$  after 72 h [Figure 1]. Anti-amastigote activity against *L. major* was found similar to Glucantime<sup>®</sup> at concentrations  $\geq 20$   $\mu\text{g}/\text{ml}$  ( $P > 0.05$ ). No significant difference in viability of amastigotes and macrophages in negative controls were observed ( $P > 0.05$ ). Osthole affected cell viability of J774.A1 macrophages at concentrations  $\geq 30$   $\mu\text{g}/\text{ml}$ .



**Figure 1:** Mean number of intracellular amastigotes in negative controls, increasing concentrations of osthole, and positive control in 12, 24, 48, and 72 h. Number of amastigotes is significantly decreased at concentrations  $\geq 20$   $\mu\text{g}/\text{ml}$  ( $P < 0.05$ )

## In vivo study

BALB/c mice infected with promastigotes of *L. major* developed progressive lesions 4 weeks after the injection of inoculum. Mice of groups C and D (DMSO-xanthan treated and untreated) developed larger lesions, ( $5.19 \pm 0.19$  mm) and ( $5.11 \pm 0.28$  mm), respectively. Mean lesion size of group A (osthole treated) was found to be significantly less compared to groups C and D ( $P < 0.05$ ;  $3.9 \pm 0.32$  mm). Unlike group B (Glucantime® treated) subsidence of lesion size did not occur in group A [Figure 2].

## DISCUSSION

Phytochemicals are a major resource for discovery of novel parasitocidal agents.<sup>[20]</sup> Osthole, a natural prenylated coumarin, is extensively studied for its significant pharmacological activities including antithrombotic,<sup>[21]</sup> antidiabetic,<sup>[22]</sup> antiosteoporotic,<sup>[23]</sup> anticancer,<sup>[24]</sup> neuroprotective,<sup>[25]</sup> and hepatoprotective;<sup>[26]</sup> still there is few data on its parasitocidal effect. This experimental study represents the first description of anti-*Leishmania* activity of osthole.

Anti-*Leishmania* activity of several coumarins has been addressed recently. Coumarins extracted from *Galipea panamensis* displayed activity against amastigotes of *Leishmania panamensis*;<sup>[27]</sup> (-) heliottin and 3-(1'-dimethylallyl)-decursinol, isolated coumarins of *Helietta apiculata* demonstrated activity against promastigote form of *Leishmania amazonensis*, and reduced the parasite load in lesions of BALB/c mice similar to Glucantime®.<sup>[28]</sup> Our results are in line with previous studies, which demonstrated the activity of prenylated coumarins, umbelliprenin, and auraptene from *Ferula szowitsiana* against *L. major*.<sup>[29]</sup> (-) mamma A/BB, a prenylated coumarin, isolated from the leaves of *Calophyllum brasiliense* was shown to be active against both promastigote and amastigote forms of *L. amazonensis* and *Leishmania braziliensis*.<sup>[16,30]</sup> and later it was shown that topical and intramuscular treatment with (-) mamma A/BB significantly decreased CL lesions of BALB/c mice similar to Glucantime®.<sup>[19]</sup>

Significant leishmanicidal activity of osthole *in vitro* inspired the researchers to conduct the *in vivo* study. Results obtained from the *in vivo* study did not demonstrate recovery of CL lesions in BALB/c mice treated with osthole; however, progression of lesions was significantly declined compared to untreated mice. Unlike untreated mice, secondary bacterial

infection was not observed in mice treated with osthole, which confirms its antibacterial activity. Osthole is reported to possess antibacterial activity against Gram-positive and Gram-negative bacteria.<sup>[31]</sup>

Microarray gene expression profile of *Mycobacterium tuberculosis* displayed that genes encoding fumarate reductase were considerably inhibited when exposed to osthole.<sup>[32]</sup> Therefore, it appears that leishmanicidal activity of osthole could be contributed by the relevant downregulation of fumarate reductase, which is an important enzyme in the parasite respiratory chain.

It should be noted that osthole is poorly soluble in most commonly used solvents, and DMSO was found appropriate to dissolve osthole. Cytotoxic effects of DMSO reported previously,<sup>[33,34]</sup> restricted the researchers to apply concentrations of osthole higher than 0.2% *in vivo*; nevertheless, it was not considered as an obstacle in the *in vitro* study due to over 200-fold dilution by the medium. Data obtained from the measurement of CL lesions in concentrations <0.2% are not discussed due to insignificant efficacy. However, results are indicative of significant decrease in lesion progression when osthole is used at 0.2%.

## CONCLUSIONS

*In vitro* study exhibits the considerable leishmanicidal activity of osthole against *L. major*. According to the *in vivo* study, osthole delays progression of CL lesions, nevertheless does not show therapeutic property when administered topically at 0.2%. Further studies on higher concentrations may demonstrate higher efficacy.

## Financial support and sponsorship

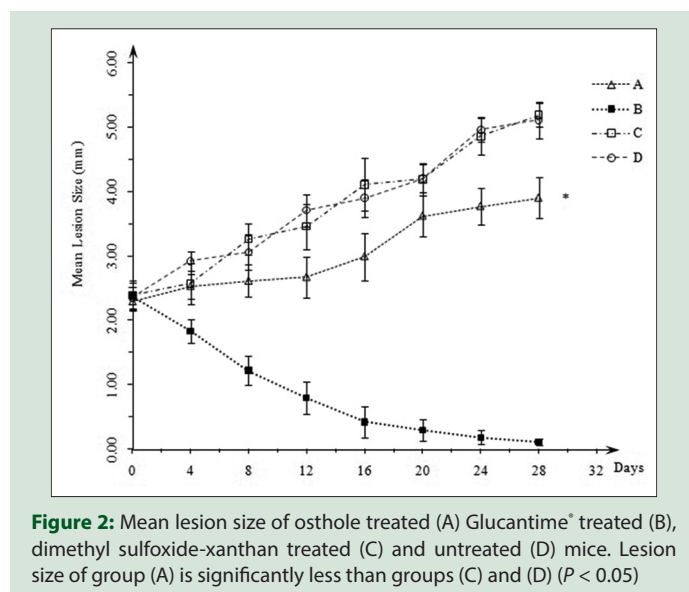
Isfahan University of Medical Sciences.

## Conflicts of interest

There are no conflicts of interest.

## REFERENCES

- World Health Organization. Control of the Leishmaniasis. World Health Organization Technical Report Series 949. Geneva: World Health Organization; 2010. p. xii-xiii.
- Minodier P, Parola P. Cutaneous leishmaniasis treatment. *Travel Med Infect Dis* 2007;5:150-8.
- Berman J. Clinical status of agents being developed for leishmaniasis. *Expert Opin Investig Drugs* 2005;14:1337-46.
- Rocha LG, Almeida JR, Macêdo RO, Barbosa-Filho JM. A review of natural products with antileishmanial activity. *Phytomedicine* 2005;12:514-35.
- Abyshev AZ. Coumarins from the fruits of *Prangos ferulacea*. *Chem Nat Compd* 1968;4:130-1.
- Kuznetsova GA, Danchul TY, Sokolova EA, Kuzmina LV. Coumarin from the roots and epigeal mass of *Prangos acaulis*. *Chem Nat Compd* 1979;15:752.
- Sajjadi SE, Zeinvand H, Shokoohinia Y. Isolation and identification of osthol from the fruits and essential oil composition of the leaves of *Prangos asperula* Boiss. *Res Pharm Sci* 2009;4:19-23.
- Baser KH, Demirci B, Demirci F, Bedir E, Weyerstahl P, Marschall H, et al. A new bisabolene derivative from the essential oil of *Prangos uechtritzii* fruits. *Planta Med* 2000;66:674-7.
- Ulubelen A, Topcu G, Tan N, Olçal S, Johansson C, Uçer M, et al. Biological activities of a Turkish medicinal plant, *Prangos platychaena*. *J Ethnopharmacol* 1995;45:193-7.
- You L, Feng S, An R, Wang X. Osthole: A promising lead compound for drug discovery from a traditional Chinese medicine (TCM). *Nat Prod Commun* 2009;4:297-302.
- Xia ML, Dun LF, XU JT. An *in vitro* test of killing effect of osthol against *Trichomonas vaginalis*. *China Trop Med* 2008;3:013.
- Wang KY, Yao L, Du YH, Xie JB, Huang JL, Yin ZQ. Anthelmintic activity of the crude extracts, fractions, and osthole from radix *Angelicae pubescentis* against *Dactylogyrus intermedius* in goldfish (*Carassius auratus*) *in vivo*. *Parasitol Res* 2011;108:195-200.
- Mehregan I, Sajjadi SE. Chemical composition of the essential oil of *Prangos*



**Figure 2:** Mean lesion size of osthole treated (A) Glucantime® treated (B), dimethyl sulfoxide-xanthan treated (C) and untreated (D) mice. Lesion size of group (A) is significantly less than groups (C) and (D) ( $P < 0.05$ )

- asperula* Boiss. Subsp. *Haussknechtii* (BOISS.) Herrnst. Etheyn fruits. *Daru J Pharm Sci* 2003;11:79-81.
14. Gamboa-León MR, Aranda-González I, Mut-Martin M, García-Miss MR, Dumonteil E. *In vivo* and *in vitro* control of *Leishmania mexicana* due to garlic-induced NO production. *Scand J Immunol* 2007;66:508-14.
  15. Zhang X, Goncalves R, Mosser DM. The isolation and characterization of murine macrophages. *Curr Protoc Immunol* 2008;83:1-14
  16. Brenzan MA, Nakamura CV, Dias Filho BP, Ueda-Nakamura T, Young MC, Cortez DA. Anti-leishmanial activity of crude extract and coumarin from *Calophyllum brasiliense* leaves against *Leishmania amazonensis*. *Parasitol Res* 2007;101:715-22.
  17. Ezatpour B, Saedi Dezaki E, Mahmoudvand H, Azadpour M, Ezzatkah F. *In vitro* and *in vivo* antileishmanial effects of *Pistacia khinjuk* against *Leishmania tropica* and *Leishmania major*. *Evid Based Complement Alternat Med* 2015;2015:149707.
  18. Chan M, Bulinski CJ, Chang KP, Fong D. A microplate assay for *Leishmania amazonensis* promastigotes expressing multimeric green fluorescent protein. *Parasitol Res* 2003;89:266-71.
  19. Tiunan TS, Brenzan MA, Ueda-Nakamura T, Filho BP, Cortez DA, Nakamura CV. Intramuscular and topical treatment of cutaneous leishmaniasis lesions in mice infected with *Leishmania amazonensis* using coumarin (-) mamea A/BB. *Phytomedicine* 2012;19:1196-9.
  20. Ndjonka D, Rapado LN, Silber AM, Liebau E, Wrenger C. Natural products as a source for treating neglected parasitic diseases. *Int J Mol Sci* 2013;14:3395-439.
  21. Ko FN, Wu TS, Liou MJ, Huang TF, Teng CM. Inhibition of platelet thromboxane formation and phosphoinositides breakdown by osthole from *Angelica pubescens*. *Thromb Haemost* 1989;62:996-9.
  22. Liang HJ, Suk FM, Wang CK, Hung LF, Liu DZ, Chen NQ, *et al.* Osthole, a potential antidiabetic agent, alleviates hyperglycemia in db/db mice. *Chem Biol Interact* 2009;181:309-15.
  23. Tang DZ, Hou W, Zhou Q, Zhang M, Holz J, Sheu TJ, *et al.* Osthole stimulates osteoblast differentiation and bone formation by activation of beta-catenin-BMP signaling. *J Bone Miner Res* 2010;25:1234-45.
  24. Yang D, Gu T, Wang T, Tang Q, Ma C. Effects of osthole on migration and invasion in breast cancer cells. *Biosci Biotechnol Biochem* 2010;74:1430-4.
  25. Chao X, Zhou J, Chen T, Liu W, Dong W, Qu Y, *et al.* Neuroprotective effect of osthole against acute ischemic stroke on middle cerebral ischemia occlusion in rats. *Brain Res* 2010;1363:206-11.
  26. Zhang J, Xue J, Wang H, Zhang Y, Xie M. Osthole improves alcohol-induced fatty liver in mice by reduction of hepatic oxidative stress. *Phytother Res* 2011;25:638-43.
  27. Arango V, Robledo S, Séon-Méniel B, Figadère B, Cardona W, Sáez J, *et al.* Coumarins from *Galipea panamensis* and their activity against *Leishmania panamensis*. *J Nat Prod* 2010;73:1012-4.
  28. Ferreira ME, de Arias AR, Yaluff G, de Bilbao NV, Nakayama H, Torres S, *et al.* Antileishmanial activity of furoquinolines and coumarins from *Helietta apiculata*. *Phytomedicine* 2010;17:375-8.
  29. Iranshahi M, Arfa P, Ramezani M, Jaafari MR, Sadeghian H, Bassarello C, *et al.* Sesquiterpene coumarins from *Ferula szowitsiana* and *in vitro* antileishmanial activity of 7-prenyloxycoumarins against promastigotes. *Phytochemistry* 2007;68:554-61.
  30. Brenzan MA, Ferreira IC, Lonardon MV, Honda PA, Filho ER, Nakamura CV, *et al.* Activity of extracts and coumarins from the leaves of *Calophyllum brasiliense* on *Leishmania braziliensis*. *Pharm Biol* 2008;46:380-6.
  31. Rosselli S, Maggio A, Bellone G, Formisano C, Basile A, Cicala C, *et al.* Antibacterial and anticoagulant activities of coumarins isolated from the flowers of *Magydaris tomentosa*. *Planta Med* 2007;73:116-20.
  32. Wei J, Guo N, Liang J, Yuan P, Shi Q, Tang X, *et al.* DNA microarray gene expression profile of *Mycobacterium tuberculosis* when exposed to osthole. *Pol J Microbiol* 2013;62:23-30.
  33. Qi W, Ding D, Salvi RJ. Cytotoxic effects of dimethyl sulphoxide (DMSO) on cochlear organotypic cultures. *Hear Res* 2008;236:52-60.
  34. Da Violante G, Zerrouk N, Richard I, Provot G, Chaumeil JC, Arnaud P. Evaluation of the cytotoxicity effect of dimethyl sulfoxide (DMSO) on Caco2/TC7 colon tumor cell cultures. *Biol Pharm Bull* 2002;25:1600-3.

## ABOUT AUTHORS

**Elaheh Kordzadeh Kermani:** School of Pharmacy and Pharmaceutical Sciences, Isfahan University of Medical Sciences.

**Seyed Ebrahim Sajjadi:** School of Pharmacy and Pharmaceutical Sciences, Isfahan University of Medical Sciences.

**Seyed Hossein Hejazi:** School of Medicine, Isfahan University of Medical Sciences.

**Reza Arjmand:** School of Medicine, Ahvaz Jundishapur University of Medical Sciences.

**Sedigheh Saberi:** School of Medicine, Isfahan University of Medical Sciences.

**Abbas Ali Eskandarian:** School of Medicine, Isfahan University of Medical Sciences.