

# Antiallergic effect of an aqueous leaf extract of *Pistia stratiotes* in murine model of ovalbumin-induced allergic conjunctivitis

Samuel Abokyi<sup>1,2</sup>, George Asumeng Koffuor<sup>1</sup>, Samuel Kyei<sup>2</sup>, Emmanuel A. Asiamah<sup>3</sup>,  
Clement Nsobire Atobiga<sup>3</sup>, Agnes Awuah<sup>2</sup>

<sup>1</sup>Department of Pharmacology, Faculty of Pharmacy and Pharmaceutical Sciences, Kwame Nkrumah University of Science and Technology, Kumasi, <sup>2</sup>Department of Optometry, School of Physical Sciences, University of Cape Coast, Cape Coast, <sup>3</sup>Department of Pathology, Komfo Anokye Teaching Hospital, Kumasi, Ghana

Submitted: 09-04-2014

Revised: 26-04-2014

Published: 06-08-2014

## ABSTRACT

**Aim:** The aim was to investigate the antiallergic effect of an aqueous leaf extract of *Pistia stratiotes* (ALPS) in a murine model of ovalbumin (OVA)-induced allergic conjunctivitis (AC). **Materials and Methods:** Prior to topical challenge (instillation of 1.5 mg OVA in 10  $\mu$ L phosphate buffered saline into their conjunctival sacs) to induce AC, groups of sensitized Imprinting Control Region mice (injected IP, on day 1 and 7, with 0.2 ml solution of 100  $\mu$ g OVA and 0.01 mg aluminum hydroxide in phosphate buffered saline), were treated with 5 mg/kg cetirizine, 10, 50 or 100 mg/kg of ALPS, or 2 ml/kg normal saline *per os*. Conjunctival redness, lid edema, tearing and lid scratching (clinical symptoms of AC) were scored. Serum OVA specific immunoglobulins were determined using ELISA. Histopathological assessment of the conjunctival mucosal tissue was conducted. The extract was screened for secondary plant metabolites. **Results:** Pretreatment with the extract significantly ( $P \leq 0.05-0.01$ ) and dose-dependently reduced the scores for clinical symptoms, which were marked in vehicle-pretreated mice. Pretreatment also lowered ( $P \leq 0.01-0.001$ ) serum OVA specific immunoglobulins. Mast cell infiltration and degranulation in conjunctival stroma (measured by an inflammatory score) in histopathological studies was also significantly low ( $P \leq 0.05-0.01$ ) on pretreatment. **Conclusion:** The ALPS exhibited interesting antiallergic activity and hence could be useful in managing AC.

**Key words:** Conjunctival redness, lid edema, mast cell degranulation, mast cell infiltration, tearing

## INTRODUCTION

Allergic conjunctivitis (AC), a predominant immunoglobulin E-mediated ocular hypersensitive reaction,<sup>[1]</sup> is globally estimated to account for more than 10% of ocular consultations.<sup>[2]</sup> Sufferers face continual ocular discomfort, such as intense itching, vision fatigue and difficulty in reading which hampers productive life,<sup>[3]</sup> and patients resolve these by using several prescribed antiallergic medications which financially burden them during periods of exacerbation.

Current treatment modalities may be inefficient and/or associated with some adverse ocular effect. Studies have shown that usage of antihistamines is associated with the development of dry eyes.<sup>[4,5]</sup> Persons being managed with steroids are predisposed to developing cataract<sup>[6]</sup> and glaucoma,<sup>[7]</sup> while users of mast cell stabilizers often do not notice alleviation of symptoms when the allergic inflammatory reaction has already set in and symptoms only seem to improve after it has been used for over 2 weeks.<sup>[1,8]</sup>

It is therefore necessary to research and discover new and effective treatment alternatives in managing AC. The suitability of the use of *Pistia stratiotes* Linn was found in its topical use as an ocular anodyne in Gambia. The antiinflammatory effect and safety of this plant's extract in the management of uveitis has been demonstrated.<sup>[9,10]</sup> In addition, *P. stratiotes* is already included in herbal

### Address for correspondence:

Dr. George Asumeng Koffuor, Department of Pharmacology,  
Faculty of Pharmacy and Pharmaceutical Sciences, Kwame  
Nkrumah University of Science and Technology, Kumasi, Ghana.  
E-mail: gkoffuor@yahoo.com

### Access this article online

#### Website:

[www.phcogres.com](http://www.phcogres.com)

DOI: 10.4103/0974-8490.138243

#### Quick Response Code:



preparations for the management of asthma; an allergic disorder of the respiratory system.<sup>[11]</sup>

It is on this premise that the antiallergic effect of an aqueous extract of *P. stratiotes* (ALPS) was investigated to determine its potential in the therapeutic management of AC.

## MATERIALS AND METHODS

### Plant collection and authentication

*Pistia stratiotes* was collected from the Fosu lagoon, in the Central Region of Ghana, in December 2010, and authenticated in the Department of Herbal Medicine, KNUST, Kumasi, Ghana where a voucher specimen (KNUST/HM1/11/W002) has been deposited.

### Preparation of aqueous leaf extract of *Pistia stratiotes*

Fresh leaves of *P. stratiotes* were washed, air-dried, and powdered using a hammer mill. A 700 g quantity of the powder was soaked in a liter of water for 24 h. Reflux filtration was performed at 80°C. The filtrate was freeze-dried with a Hull freeze-dryer/lyophilizer 140 SQ FT (model 140FS275C; Hull, Warminster, PA), labeled ALPS, and stored at 4°C (yield 4.7%).

### Phytochemical screening of aqueous leaf extract of *Pistia stratiotes*

Aqueous leaf extract of *P. stratiotes* was screened following recommended protocols described for the presence of phytochemicals by Trease and Evans.<sup>[12]</sup>

### Ethical and biosafety considerations

The study protocols were approved by the Departmental Ethics Committee. All activities performed during the studies conformed to accepted principles for laboratory animal use and care (EU directive of 1986: 86/609/EEC). Biosafety guidelines for protection of personnel in the laboratory were observed.

### Drugs and chemicals

Ovalbumin (OVA) (Cayla-InvivoGen, Toulouse, France), Aluminum hydroxide (Hopkins and Williams Limited, Chadwell Heath, Essex, UK), chloroform (VWR International Ltd, Leicester, UK), and formalin (Yash Chemicals, India) were some chemicals used in this study.

### Experimental animals

Eight-week old Imprinting Control Region (ICR) mice of either sex weighing 18-24 g were provided by the Animal House Unit of the Department of Pharmacology, KNUST, Kumasi, Ghana. These animals were kept in metallic cages under ambient conditions of temperature ( $26 \pm 3^\circ\text{C}$ ), relative humidity (60-70%) and light/dark cycles. Mice

were given normal commercial mice chow pellet from Agricare Limited, Kumasi, Ghana, and water *ad libitum*. Mice were made to acclimatize to the laboratory condition for at least 1 week before experimentation.

### Sensitization, challenge and induction of allergic conjunctivitis

Allergic conjunctivitis was induced using active immunization protocols for the murine model as described below.<sup>[13]</sup> Mice were sensitized by intraperitoneal injection with 0.2 ml solution containing 100 µg OVA and 0.01 mg aluminum hydroxide in phosphate buffer saline of pH 7.4. Immunization was repeated after 7 days to last another week. On day 15, sensitized mice were challenged by instillation of 1.5 mg OVA in 10 µL phosphate buffered saline into the conjunctival sacs of each eye 2 times. This was repeated on day 18. Conjunctival redness, lid edema, tearing, and lid scratching in mice were the clinical symptoms of AC induced.

### Pretreatment and assessment of clinical scores of ovalbumin-induced allergic conjunctivitis

Sensitized mice were put into six groups ( $n = 7$ ). Groups I–V were treated with either 2 ml/kg normal saline (NS), 5 mg/kg cetirizine (CET), or 10, 50 or 100 mg/kg ALPS respectively, 1 h before OVA challenge. Group VI was not challenged. A normal control Group (VII) was also kept under experimental conditions. Conjunctival redness, lid edema, and tearing were observed under a SL500 Shin Nippon Slit Lamp (Ajinomoto Trading Inc., Tokyo, Japan), were scored on a scale of 0-3 30 min after the last topical challenge.<sup>[14]</sup> Lid scratching was monitored for 30 s, and the frequency of scratching was counted. Only one eye of each animal was assessed and data presented as the mean per group.

### Ovalbumin-specific antibodies assay

Mice were anesthetized with chloroform and blood collected by cardiac puncture into Eppendorf tubes (Sigma-Aldrich, St. Louis, MO, USA) and allowed to clot. The clotted blood was centrifuged (temperature 25°C, speed 3000 g) for 5 min using a Mikro 220R machine (Hettich Zentrifuge, Tuttlingen, Germany). Serum obtained was subjected to the protocol outlined by manufacturers of mouse OVA-specific IgE ELISA kit (Biolegend, San Diego, CA). Coloration proportionate to IgE concentration in samples was obtained. Absorbances were read at 450 nm by a plate reader (Thermo Scientific Multiskan EX, Vantaa, Finland) within 10 min from which concentrations were estimated.

### Histopathological assessment

The eyes including conjunctiva and lids were exenterated and fixed in 10% buffered formalin. Conjunctival

tissue sections (4-5  $\mu$  thick) were made using rotary microtome and stained with hematoxylin and eosin and histological observations were made under light microscope. Considering hot spots in each conjunctival tissue section, the degree of inflammation (i.e. the extent of mast cell infiltration and degranulation) was scored [Table 1].

### Statistical analysis

Statistical significance was ascertained using the unpaired *t*-test (two-tailed), and one-way analysis of variances followed by Dunnett's test *post-hoc*, provided by GraphPad Prism 5 (GraphPad Software, Inc., San Diego, CA).  $P \leq 0.05$  were considered to be significant.

## RESULTS

### Phytochemical screening

Preliminary screening of ALPS indicated the presence of alkaloids, glycosides, steroids, flavonoids, and tannins.

### Antiallergic effect

After sensitization and challenge, there was about seven fold increase in the mean clinical AC score for OVA-induced AC (OIAC) compared with normal mice ( $2.60 \pm 0.07$  vs.  $0.40 \pm 0.06$ ,  $P \leq 0.001$ ). Pretreatments with ALPS significantly and dose-dependently reduced ( $P \leq 0.05-0.01$ ) conjunctival redness, chemosis, tearing and lid scratching [Table 2]. There was, however, no significant difference ( $P > 0.05$ ) between OIAC and pretreatment with NS.

**Table 1: Scoring of inflammation of the conjunctiva in OIAC in ICR mice**

Score	Degree of inflammation	Mast cell infiltrations per conjunctival section (%)
0	Normal	<30
1	Mild	$\geq 30$ but <50
2	Moderate	$\geq 50$ but <70
3	Marked	$\geq 70$ but <100
4	Severe	100

ICR: Imprinting Control Region, OIAC: Ovalbumin-induced allergic conjunctivitis

**Table 2: Scores for clinical assessment of ocular inflammatory response in normal ICR mice, OIAC and AC mice pretreated with CET and ALPS**

Signs of AC	Normal	OIAC	2 ml/kg NS	5 mg/kg CET	10 mg/kg ALPS	50 mg/kg ALPS	100 mg/kg ALPS
Conjunctival redness	$0.29 \pm 0.18$	$2.78 \pm 0.20^{\text{ppp}}$	$2.93 \pm 0.18^{\text{ns,fff}}$	$1.25 \pm 0.25^{**,\text{ff}}$	$1.83 \pm 0.20^{*,\text{ff}}$	$1.59 \pm 0.18^{*,\text{ff}}$	$1.33 \pm 0.18^{**,\text{ff}}$
Chemosis	$0.43 \pm 0.20$	$2.55 \pm 0.18^{\text{ppp}}$	$2.70 \pm 0.20^{\text{ns,fff}}$	$1.14 \pm 0.14^{**,\text{ns}}$	$1.58 \pm 0.18^{*,\text{fff}}$	$1.71 \pm 0.18^{*,\text{fff}}$	$1.43 \pm 0.20^{**,\text{ff}}$
Tearing	$0.29 \pm 0.18$	$2.85 \pm 0.14^{\text{ppp}}$	$2.54 \pm 0.25^{\text{ns,fff}}$	$0.57 \pm 0.20^{***,\text{ns}}$	$1.63 \pm 0.20^{*,\text{fff}}$	$1.64 \pm 0.14^{*,\text{fff}}$	$1.50 \pm 0.00^{*,\text{fff}}$
Lid scratch	$0.57 \pm 0.20$	$2.69 \pm 0.30^{\text{ppp}}$	$2.81 \pm 0.35^{\text{ns,fff}}$	$0.71 \pm 0.18^{***,\text{fff}}$	$1.74 \pm 0.25^{*,\text{fff}}$	$2.14 \pm 0.20^{\text{ns,fff}}$	$1.43 \pm 0.25^{**,\text{fff}}$
Mean clinical AC score	$0.40 \pm 0.06$	$2.60 \pm 0.07^{\text{ppp}}$	$2.75 \pm 0.08^{\text{ns,fff}}$	$0.92 \pm 0.16^{***,\text{ns}}$	$1.69 \pm 0.06^{*,\text{fff}}$	$1.71 \pm 0.20^{*,\text{fff}}$	$1.42 \pm 0.04^{**,\text{fff}}$

Values are mean  $\pm$  SEM,  $n=7$ . Differences between normal and OIAC:  $^{\text{ppp}}P \leq 0.0001$  (unpaired *t*-test, two-tailed), Differences between OIAC and treatment groups:  $^*P \leq 0.05$ ;  $^{**}P \leq 0.01$ ;  $^{***}P \leq 0.001$ , Difference between normal and treatment groups:  $^{\text{ff}}P \leq 0.01$ ;  $^{\text{fff}}P \leq 0.001$  (One-way ANOVA followed by multiple Dunnett's *post-hoc* test),  $^{\text{ns}}P > 0.05$ . ICR: Imprinting Control Region, OIAC: Ovalbumin-induced allergic conjunctivitis, CET: Cetirizine, ALPS: Aqueous leaf extract of *Pistia stratiotes*, AC: Allergic conjunctivitis, NS: No significant, SEM: Standard error of the mean

### Ovalbumin-specific antibodies assay

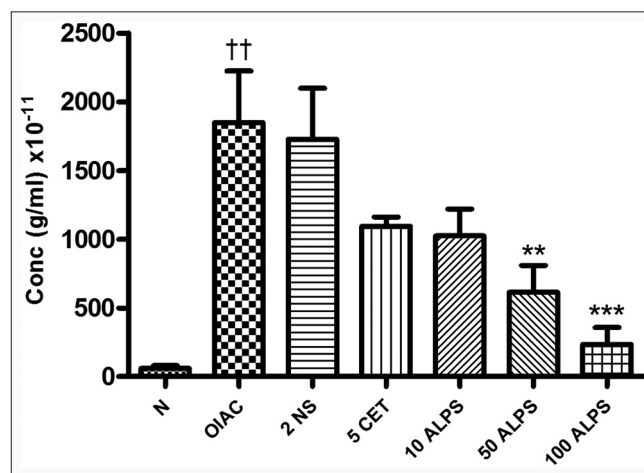
Sera concentrations of OVA-specific IgE were significantly elevated ( $P \leq 0.01$ ) on induction of AC. ALPS (50, and 100 mg/kg) pretreatment before OIAC significantly lowered ( $P \leq 0.01-0.001$ ) serum OVA-specific IgE while no significant difference ( $P > 0.05$ ) was observed with CET pretreatment [Figure 1].

### Histopathology assessment

Mice with OIAC had very significantly high ( $P \leq 0.001$ ) inflammatory score as mast cell infiltration and degranulation was very high in the conjunctival stroma [Figure 2b]. Mast cell infiltration and degranulation however was significantly low in the conjunctival stroma of mice pretreated with ALPS and CET [Figure 2c-g]. Inflammatory scores were significantly lower ( $P \leq 0.05-0.01$ ) with pretreatment [Figure 3].

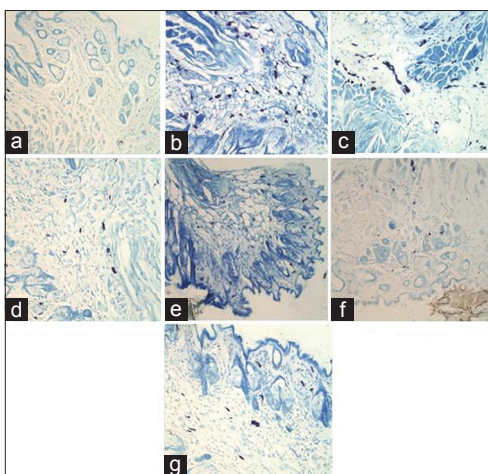
## DISCUSSION

Allergic conjunctivitis was induced in ICR mice after sensitization and challenge with OVA. OVA is a



**Figure 1:** Sera concentration of IgE in ovalbumin (OVA) - induced allergic conjunctivitis (OIAC) in sensitized Imprinting Control Region mice pretreated with 2 ml/kg normal saline, 5 mg/kg cetirizine, or 10, 50, and 100 mg/kg aqueous leaf extract of *Pistia stratiotes* followed by challenge with OVA. Normal versus OIAC:  $^{\text{ff}}P \leq 0.01$ . OIAC versus treatments:  $^{**}P \leq 0.01$ ,  $^{***}P \leq 0.001$





**Figure 2:** Histopathology of conjunctival tissue of normal and ovalbumin-induced allergic conjunctivitis in Imprinting Control Region mice. (a) Normal conjunctival epithelium and stroma, (b) OIAC in ICR mice showing increased mast cell infiltration and degranulation in conjunctive stroma, (c) Normal saline-Treated OIAC showed significant infiltration and degranulation of mast cells after treatment with normal saline, (d) Cetirizine-Treated OIAC showing minimal infiltration of intact mast cells in conjunctival stroma, (e) 10 mg/kg ALPS treated OIAC showing minimal infiltration of intact mast cells in conjunctival epithelium and stroma, (f) 50 mg/kg ALPS-treated OIAC showing significant reduced mast cell population in conjunctival stroma, (g) 100 mg/kg ALPS-treated OIAC showing significant reduced mast cell population in conjunctival epithelium and stroma

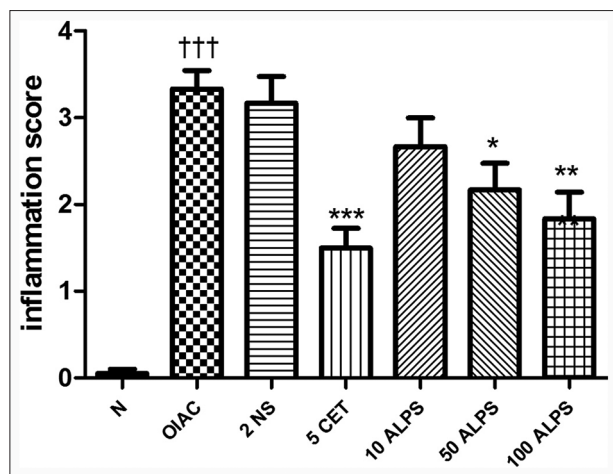
phosphorylated glycoprotein having 386 amino acid residues, and a molecular weight of approximately 45 kDa.<sup>[15]</sup> OVA has several mannose (carbohydrate) residues, which binds to the mannose receptors expressed by antigen presenting cells such as macrophages, dendritic cells (DCs), and monocytes.<sup>[16,17]</sup> Studies have also identified some specific peptides of OVA contains both T and B cell epitopes.<sup>[18]</sup> Injection of OVA in combination with aluminum hydroxide adjuvance enhances an immune response by induction of inflammation resulting in the release of uric acid from necrotic cells,<sup>[19]</sup> leading to recruitment and differentiation of monocytes to DCs which phagocytose and presents it as linear peptides (having T and B cell epitopes) bound to Class II major histocompatibility complex (MHC) molecules. Naïve T helper (Th0) cells bind by their T cell receptors to the MHC (II) complex resulting in the activation and differentiation into Th2 cells, which are vital in allergic inflammatory process. Th2 cells produce cytokines like interleukin (IL)-4, IL-5, IL-9 and IL-13 that are involved in the activation and differentiation of B cells to memory B cells and the class-switching of B cells to allergen-specific IgE synthesis as well as the recruitment of mast cells. These were evident from the increased sera IgE and massive mast cell infiltrations observed in the ocular tissues OIAC mice compared with the normal. Sensitization is completed after IgE attaches to high-affinity IgE receptors on mast cells. During the local ocular challenge, the

allergen-specific IgE antibodies were cross-linked by IgE binding epitopes resulting in degranulation of the mast cells and the release of histamine. The consequences of histamine release from degranulated mast cell were characterized by manifestations of significantly increased lid scratching, conjunctival redness, chemosis and tearing observed in the OIAC mice.

While mast cells are considered to be principally effector cells in the pathogenesis of the early phase of allergic response, studies have found that mast cells also participate in the late phase of through the recruitment of inflammatory cells including Th2 lymphocytes and eosinophils through the action of prostaglandin D2.<sup>[20]</sup> While eosinophil infiltration usually characterizes the late phase of allergic induction, its absence has been noticed in some murine models indicating that it is not a prerequisite,<sup>[21]</sup> but may rather exert regulatory functions instead of an effector or proinflammatory role in chronic allergies.<sup>[22]</sup>

Cetirizine, very significantly reduced clinical signs of AC and mast cell infiltrations but not the sera IgE. This was because IgE synthesis and mast cell degranulation precede histamine release and stimulation of histamine receptors, which is the target for antihistamines. H1 receptor stimulation is chiefly responsible for nerve end stimulation and vasodilation<sup>[23]</sup> resulting in ocular symptoms such as itching, redness, chemosis and tearing experienced by sufferers of ocular allergy. The preferential H1-selectivity, safety and rapid onset of action of CET make it a favorable drug in the management of ocular allergy. Apart from acting as histamine receptor antagonists, CET and its derivatives have also been observed to exhibit anti-inflammatory activity,<sup>[24]</sup> which could explain the decreased mast cell infiltration observed in the ocular tissue.

Aqueous leaf extract of *P. stratiotes* significantly reduced clinical symptoms, sera OVAs-IgE concentration and mast infiltration and degranulation [Figures 2 and 3], indicating antiallergic and/or antiinflammatory effect. A study that has already explored the antiinflammatory activity of *P. stratiotes* observed that this extract was effective in the management of inflammatory disorders such as fever and arthritis with activity comparable to standard antiinflammatory drugs such as methotrexate, diclofenac, and dexamethasone.<sup>[25]</sup> A recent study involving the use of the extract in the successful management of a sight threatening intraocular inflammatory disease is also documented.<sup>[10]</sup> While it's antiallergic potential may not be well-known, *P. stratiotes* is already purported to be among some herbal preparations in the management of asthma.<sup>[11]</sup>



**Figure 3:** Ocular histological assessment showing degree of inhibition of ovalbumin (OVA)-induced allergic conjunctivitis (OIAC) in sensitized Imprinting Control Region mice pretreated with 2 ml/kg normal saline, 5 mg/kg cetirizine, or 10, 50, and 100 mg/kg aqueous leaf extract of *Pistia stratiotes* followed by challenge with OVA. OIAC versus normal: ††† $P \leq 0.001$ . OIAC versus treatments: \*\* $P \leq 0.05$ , \*\*\* $P \leq 0.01$ , \*\*\*\* $P \leq 0.001$

The activity of *P. stratiotes* could be due to the collective effects of alkaloids, glycosides, steroids, flavonoids, and tannins; the secondary plant metabolites present. Studies have identified specific bioactive steroids such as stigmasta-4, 22-dien-3-one, stigmasterol, stigmasteryl stearate, and palmitic acids and other flavonoid glycosides such as 2-di-C-glycosylflavones of vicenin and lucenin type, anthocyanin-cynidin-3-glucoside, luteolin-7-glycoside and mono-C-glycosyl flavones-vitexin and orientin.<sup>[26]</sup>

While most classes of phytochemicals have shown immunomodulatory activities, the flavonoids have received a great deal of attention for their anti-inflammatory and antiallergic properties. These effects are achieved through diverse mechanisms of actions proposed by these metabolites. For instance, quercetin, a flavonoid inhibits both cyclooxygenase and 5-lipoxygenase pathways for prostacyclin and leukotriene synthesis.<sup>[27]</sup> Quercetin has also been reported to inhibit histamine release by allergen-stimulated human basophils.<sup>[28]</sup> Luteolin glycosides are claimed to be the most potent inhibitor of histamine release from mast cells.<sup>[29]</sup> Reports by Hirano *et al.*<sup>[30]</sup> that luteolin inhibits the CD40 ligand expression by basophils and mast cells and cytokine synthesis make flavonoids natural potential IgE inhibitors.

## CONCLUSION

The ALPS exhibited interesting antiallergic activity and hence could be useful in managing AC.

## REFERENCES

1. La Rosa M, Lionetti E, Reibaldi M, Russo A, Longo A, Leonardi S, *et al.* Allergic conjunctivitis: A comprehensive review of the literature. *Ital J Pediatr* 2013;39:18.
2. Katalaris CH. Ocular allergy in the Asia Pacific region. *Asia Pac Allergy* 2011;1:108-14.
3. Mangione CM, Lee PP, Gutierrez PR, Spritzer K, Berry S, Hays RD, *et al.* Development of the 25-item National Eye Institute Visual Function Questionnaire. *Arch Ophthalmol* 2001;119:1050-8.
4. Ousler GW, Wilcox KA, Gupta G, Abelson MB. An evaluation of the ocular drying effects of 2 systemic antihistamines: Loratadine and cetirizine hydrochloride. *Ann Allergy Asthma Immunol* 2004;93:460-4.
5. Abokyi S, Koffuor GA, Abu EK, Kyei S, Abraham CH. Dry eyes: An adverse effect of systemic antihistamine use in allergic conjunctivitis management. *Res J Pharmacol* 2012;6:71-7.
6. Allen MB, Ray SG, Leitch AG, Dhillon B, Cullen B. Steroid aerosols and cataract formation. *BMJ* 1989;299:432-3.
7. Mohan R, Muralidharan AR. Steroid induced glaucoma and cataract. *Indian J Ophthalmol* 1989;37:13-6.
8. Abelson MB, Chapin MJ. Current and future topical treatments for ocular allergy. *Compr Ophthalmol Update* 2000;1:303-17.
9. Koffuor GA, Kyei S, Woode E, Ekuadzi E, Ben IO. Possible mechanism of anti-inflammatory activity and safety profile of aqueous and ethanolic leaf extracts of *Pistia stratiotes* Linn (Araceae). *J Ghana Sci Assoc* 2012;14:69-81.
10. Kyei S, Koffuor GA, Boampong JN, Owusu-Afriyie O. Ocular anti-inflammatory effect of aqueous and ethanolic leaf extracts of *Pistia stratiotes* Linn (Araceae) in endotoxin-induced uveitis. *J Nat Pharm* 2012;3:115-22.
11. Amit AA, Abhay Kumar SS. Herbal drugs used for the treatment of asthma: An overview. *Int J Cur Biomed Phar Res* 2011;1:67-79.
12. Kanthal LK, Dey A, Satyavathi K, Bhojaraju P. GC-MS analysis of bio-active compounds in methanolic extract of *Lactuca runcinata* DC. *Pharmacognosy Res* 2014;6:58-61.
13. Groneberg DA, Bielory L, Fischer A, Bonini S, Wahn U. Animal models of allergic and inflammatory conjunctivitis. *Allergy* 2003;58:1101-13.
14. Ozaki A, Seki Y, Fukushima A, Kubo M. The control of allergic conjunctivitis by suppressor of cytokine signaling (SOCS) 3 and SOCS5 in a murine model. *J Immunol* 2005;175:5489-97.
15. Nisbet AD, Saundry RH, Moir AJ, Fothergill LA, Fothergill JE. The complete amino-acid sequence of hen ovalbumin. *Eur J Biochem* 1981;115:335-45.
16. Burgdorf S, Lukacs-Kornek V, Kurts C. The mannose receptor mediates uptake of soluble but not of cell-associated antigen for cross-presentation. *J Immunol* 2006;176:6770-6.
17. Autenrieth SE, Soldanova I, Rösemann R, Gunst D, Zahir N, Kracht M, *et al.* *Yersinia enterocolitica* YopP inhibits MAP kinase-mediated antigen uptake in dendritic cells. *Cell Microbiol* 2007;9:425-37.
18. Janssen EM, Wauben MH, Jonker EH, Hofman G, Van Eden W, Nijkamp FP, *et al.* Opposite effects of immunotherapy with ovalbumin and the immunodominant T-cell epitope on airway eosinophilia and hyperresponsiveness in a murine model of allergic asthma. *Am J Respir Cell Mol Biol* 1999;21:21-9.
19. HogenEsch H. Mechanisms of stimulation of the immune response by aluminum adjuvants. *Vaccine* 2002;20 Suppl 3:S34-9.
20. Hirai H, Tanaka K, Yoshie O, Ogawa K, Kenmotsu K, Takamori Y, *et al.* Prostaglandin D2 selectively induces chemotaxis in T helper type 2 cells, eosinophils, and basophils via seven-transmembrane receptor CRTH2. *J Exp Med* 2001;193:255-61.

21. Tournoy KG, Kips JC, Schou C, Pauwels RA. Airway eosinophilia is not a requirement for allergen-induced airway hyperresponsiveness. *Clin Exp Allergy* 2000;30:79-85.
22. Alam R, Busse WW. The eosinophil – Quo vadis? *J Allergy Clin Immunol* 2004;113:38-42.
23. Bielory L, Ghafoor S. Histamine receptors and the conjunctiva. *Curr Opin Allergy Clin Immunol* 2005;5:437-40.
24. Walsh GM. The anti-inflammatory effects of levocetirizine – Are they clinically relevant or just an interesting additional effect? *Allergy Asthma Clin Immunol* 2009;5:14.
25. Kyei S, Koffuor GA, Boampong JN. The efficacy of aqueous and ethanolic leaf extracts of *Pistia stratiotes* linn in the management of arthritis and fever. *J Med Biomed Sci* 2012;1:29-37.
26. Zennie TM. The flavonoid chemistry of *Pistia stratiotes*. *Aquat Bot* 1997;3:49-54.
27. Ferrándiz ML, Alcaraz MJ. Anti-inflammatory activity and inhibition of arachidonic acid metabolism by flavonoids. *Agents Actions* 1991;32:283-8.
28. Middleton E Jr, Kandaswami C. Effects of flavonoids on immune and inflammatory cell functions. *Biochem Pharmacol* 1992;43:1167-79.
29. Inoue T, Sugimoto Y, Masuda H, Kamei C. Antiallergic effect of flavonoid glycosides obtained from *Mentha piperita* L. *Biol Pharm Bull* 2002;25:256-9.
30. Hirano T, Arimitsu J, Higa S, Naka T, Ogata A, Shima Y, *et al.* Luteolin, a flavonoid, inhibits CD40 ligand expression by activated human basophils. *Int Arch Allergy Immunol* 2006;140:150-6.

**Cite this article as:** Abokyi S, Koffuor GA, Kyei S, Asiamah EA, Atobiga CN, Awuah A. Antiallergic effect of an aqueous leaf extract of *Pistia stratiotes* in murine model of ovalbumin-induced allergic conjunctivitis. *Phcog Res* 2014;6:274-9.

**Source of Support:** Nil, **Conflict of Interest:** None declared.