

Indigenous anti-ulcer activity of *Musa sapientum* on peptic ulcer

P. Prabha, Thirunethiran Karpagam^{1*}, B. Varalakshmi¹, A. Sohna Chandra Packiavathy

PG and Research Department of Biochemistry, PRIST University, Thanjavur - 614904, ¹Department of Biochemistry, Shrimati Indira Gandhi College, Tiruchirappalli-620002, Tamilnadu, India

Submitted: 24-11-2010

Revised: 13-01-2011

Published: 15-11-2011

ABSTRACT

Background: Peptic ulcer disease (PUD), encompassing gastric and duodenal ulcers is the most prevalent gastrointestinal disorder. The pathophysiology of PUD involves an imbalance between offensive factors like acid, pepsin and defensive factors like nitric oxide and growth factors. The clinical evaluation of antiulcer drugs showed tolerance, incidence of relapses and side-effects that make their efficacy arguable. An indigenous drug like *Musa sapientum* possessing fewer side-effects is the major thrust area of present day research, aiming at a better and safer approach for the management of PUD. **Material and Methods:** The unripe plantain bananas (*Musa sapientum*) were shade-dried, powdered and used for phytochemical analysis and as antiulcer drug. In our present study Group I rats served as control and were treated with saline, Group II was indomethacin-induced ulcerated rats, Group III received aqueous extract of *Musa sapientum* along with indomethacin and Group IV received esomeprazole along with indomethacin for 21 days. The anti-ulcerogenic activity was investigated by performing hematological, mucosal, antioxidant profile in comparison with the standard drug esomeprazole. **Results:** Our findings from High - Performance Thin Layer Chromatography (HPTLC) analysis showed that *Musa sapientum* has an active compound a monomeric flavonoid (leucocyanidin) with anti-ulcerogenic activity. Results were expressed as mean \pm SD. All our results are in congruous with the results of standard drug esomeprazole. **Conclusion:** It could be clearly concluded that administration of the aqueous extract of *Musa sapientum* at the dose used in this study tends to ameliorate ulcers. Its use in indigenous medicine should be scientifically scrutinized with further research.

Key words: Esomeprazole, gastric mucosa, leucocyanidin, *Musa sapientum*

INTRODUCTION

Peptic ulcer is a sore that forms in the lining of the stomach or the duodenum. A peptic ulcer results from an imbalance between some endogenous aggressive factor(s) [hydrochloric acid, pepsin, refluxed bile, leukotrienes, reactive oxygen species (ROS)] and cytoprotective factors, which include the function of the mucus-bicarbonate barrier, surface active phospholipids, prostaglandins (PGs), mucosal blood flow, cell renewal and migration, non-enzymatic and enzymatic antioxidants and some growth factors.^[1] The pathogenesis of ulcers is multifactorial and includes diverse factors such as a stressful lifestyle,

alcohol consumption, use of steroidal and nonsteroidal anti-inflammatory drugs (NSAIDs) and drugs which stimulate gastric acid and pepsin secretion, *Helicobacter pylori* infections, smoking, lower socioeconomic status and family history.^[2]

The main therapeutic target is the control of gastric secretion using antacids, H₂ receptor blockers like ranitidine, famotidine, anticholinergics like pirenzepin, telezepine or proton pump blockers like omeprazole, lansoprazole, etc.^[3] The prevention or cure of peptic ulcers is one of the most challenging problem in medicine because gastric ulcer therapy faces drawbacks and most of the drugs currently available in the market show limited efficacy against gastric diseases and are often associated with severe side-effects.^[4]

Various plants are used to cure peptic ulcers. The medicinal

Access this article online

Website:

www.phcogres.com

DOI:

10.4103/0974-8490.89742

Quick Response Code:



Address for correspondence:

Mrs Thirunethiran Karpagam,
Department of Biochemistry, Shrimati Indira Gandhi College,
Tiruchirappalli-620 018, Tamil Nadu, India.
E-mail: karpagam_murugan@yahoo.com

properties of these plants are attributed mainly to the presence of flavonoids, but they may be also influenced by other organic and inorganic compounds such as coumarins, alkaloids, terpenoids, tannins, phenolic acids and antioxidant micronutrients, e.g., copper, manganese, zinc.^[5] *Musa sapientum* fruits have been reported to prevent various disorders. Green unripe *Musa sapientum* have been reported to have protective action against gastric mucosal injury in rats.^[6] It has an effect on the healing of the ulcer.^[7] Herbal drugs are prescribed widely even when their biologically active compounds are unknown because of their effectiveness, lesser side-effects and relative low cost.^[8]

Although many natural foods promote mucous production, many people have recognized the value of the banana as an antiulcerogenic agent. The most common form of banana used is the plantain or vegetable banana. Plantains have to be cooked to be edible whereas sweet bananas are eaten raw. However, in terms of both active phytochemicals and therapeutic efficacy, both varieties of bananas seem to be similarly effective.^[7] Hence our study was designed to assess the efficacy of *Musa sapientum* powder against indomethacin-induced peptic ulcer in rats.

MATERIALS AND METHODS

Adult male albino rats weighing about 150-250 g were purchased from the animal house Mayavaram, Tamil Nadu, India and were maintained under standard conditions, fed with a standard diet (Hindustan Lever, India) and water *ad libitum*. The experiments were designed as per guidelines of the institutional ethical committee.

Drugs such as indomethacin and esomeprazole used in the experiment were purchased from Micro Labs Ltd. and Glenmark Pvt. Ltd. respectively and other chemicals used were of analytical grade.

Unripe plantain banana (*Musa sapientum*) was collected from Tiruchirapalli, Tami Nadu, India, made into pieces, shade dried, powdered and used for phytochemical analysis and as an anti-ulcerogenic agent. Five grams of coarse powder was extracted by cold extraction process using ethanol, methanol, chloroform, benzene, ethyl acetate and water.

Phytochemical Screening

Preliminary phytochemical screening of the extract was carried out as per the methods and tests given by Dey and Raman.^[9]

The phytochemical compounds in *Musa sapientum* were determined by using High-Performance Thin Layer Chromatography (HPTLC) Technique (CAMAG Linomat 5 using the software win CAT Planar Chromatography

Manager). The mobile phase was Chloroform: ethanol: water (7: 3: 0.5) for flavonoids.

1 g of powdered drug was extracted with methanol. Filtered the extract and Concentrated the extract to 10 ml. Apply 5 µl, 10 µl, 15 µl, of *Musa sapientum* extract on a precoated silica gel 60F₂₅₄ plate (E. Merck) of uniform thickness of 0.2 mm. Developed the plate in the solvent system to a distance of 7.8 cm. Observed the plate under ultraviolet (UV) light at 254 nm and 366 nm. And then scan the plate at 254 nm. Note the Retention factor (R_f) and colors of the resolved bands.

Experimental Design

The rats were divided into four groups (n = 6). Group I served as a control and received 0.9% saline. Indomethacin was administered as an ulcer inducer except in the controls. Group II consisted of indomethacin-induced ulcerogenic rats. Group III received aqueous extracts of *Musa sapientum*, Group IV received standard drug esomeprazole subcutaneously for 21 days. Both *Musa sapientum* and esomeprazole were given as co-treatment.

Musa sapientum (100 mg/kg b.w) was used as an anti-ulcerogenic drug.^[10] Indomethacin (used as reference NSAID) was administered (20 mg/kg b.w) by oral gavages to induce gastric lesions in rats.^[11] Eesomeprazole was used as standard drug and was administered subcutaneously (20 mg/kg b.w) to experimental animals.^[12]

At the end of the experimental period, rats were sacrificed by cervical decapitation. Blood was collected and an aliquot of blood was used for hematological analysis. The remaining blood sampled was centrifuged and used for further analysis. Gastric tissues were dissected out, washed with ice cold saline, homogenized, centrifuged and used for mucosal and antioxidant profiles.

Estimation of Hemoglobin

Hemoglobin was determined by the method followed by Robert.^[13]

Five milliliters of buffered cyanide/ ferri cyanide reagent was pipetted into clean and dry test tubes; 0.02 ml of blood was added to the same tubes. The pipette was thoroughly flushed with reagent. The solution was mixed well and incubated at 30 °C. Absorbance A of sample was read against distilled water after 3 min at 546 nm. The concentration 'C' of hemoglobin was calculated as follows:

$$C = 36.77 \times A \text{ (g/100 ml)}$$

Total White Blood Count

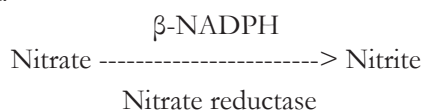
(The total white blood cells (WBCs) were enumerated by the method of Robert.)^[13]

Blood was drawn exactly to the 0.5 mark in a white blood cell diluting pipette. Immediately diluting fluid (Glacial acetic acid – 2 cc, gentian violet - 0.025 g, distilled water made up to –100ml) was also drawn to the 11 mark. Mix the contents of the pipette for 3-5 min, load a drop at the junction of the cover glass and the Neubauer counting chamber. Count the white cells in the four large corner squares contain sixteen smaller secondary squares, each with an area of 0.04 mm².

$$\text{WBC per cu mm} = \frac{\text{Number of WBC X dilution (20)}}{\text{Volume (0.4)}}$$

Estimation of Nitric Oxide in Serum and Gastric Mucosa

The serum and supernatant from tissue homogenate were taken for nitric oxide assay. Incubated the tubes at 25°C containing 250 µl of 100 mM/l of potassium phosphate buffer (pH 7.5), 50 µl of 12 mM/l of beta Nicotinamide-Adenine Dinucleotide Phosphate reduced (β-NADPH) and 100 µl of sample, add 40 µl of 500 U/l nitrate reductase and incubate the tubes in dark for 45 min. Optical density was read at 340 nm. oxidation of β-NADPH was monitored by the decrease in absorbance. The results were expressed as µmol/l.



Estimation of Hexosamine

Hexosamine was estimated by the method of Wagner.^[15]

To 0.4 ml of hydrolyzed sample, water was added to make up the solution to 1.0 ml and blank contained 1.0 ml of water. To each tube, 0.6 ml of acetyl acetone reagent (2% of acetyl acetone in 0.5 N sodium carbonate) was added, corked and heated in a boiling water bath for 30 min and cooled. To this, 2.0 ml of Ehrlich's reagent (320 mg of p-dimethyl amino benzaldehyde dissolved in 21.0 ml of isopropanol and 3.0 ml of concentrated hydrochloric acid) was added. All the tubes were shaken well and read at 540 nm. Standards containing 50-150 µg of hexosamine were also processed in the same manner. The content of hexosamine was expressed µg/100 mg of tissue.

Estimation of Protein (Protein content was determined by the method of Lowry *et al.*)

0.1 ml of tissue homogenate was made up to 1.0 ml with distilled water and then 1.0 ml 10% Trichloro acetic acid (TCA) was added. The mixture was centrifuged, supernatant discarded and the precipitate was dissolved in 1.0 ml of 0.1N sodium hydroxide. From this, aliquots were taken for the estimation; 4.5 ml of alkaline copper reagent

was added to all the tubes and the contents were allowed to stand at 37°C for 10 min. Then 0.5 ml diluted Folin's phenol reagent (1:10 dilution) was added and mixed. A series of standards with a concentration range of 20-100 g and a blank were processed in a similar manner.^[16]

Total protein content in the plasma is expressed as g/dl.

Estimation of Sialic acid (Sialic acid was estimated by the method of Winzler.)

0.4 ml glycoprotein precipitate from the gastric mucosa was dissolved in 2.0 ml of sulphuric acid and hydrolyzed. 0.2 ml of the hydrolysate was treated with 0.25 ml of periodate solution (22.5 mM in 0.1 N sulphuric acid) and left at 37°C for 30 min; 2.0 ml of thiobarbituric acid was added and heated in a boiling water bath for exactly 8 min. The tubes were cooled, acidified n-butanol was added and the pink butanol phase was extracted by centrifugation. Standard solution containing 10-40 µg of N-acetyl neuraminic acid in 0.1 N sulphuric acid was treated with periodate for condensation with thiobarbituric acid as indicated for test samples.^[17] The absorbance was read at 540 nm against a blank treated in the same way. The levels of sialic acid were expressed as µg/100 mg of tissue.

Measurement of volume and pH of gastric juice (The gastric juice was collected according to the method of Shay *et al.*)^[18]

Rats were killed by decapitation 6 h after indomethacin administration. Their stomachs were removed following ligation of the esophocardiac junction, washed with saline, dried between filter paper and opened along the greater curvature. The gastric juice was drained, the volume was measured and pH was determined.

Statistical Analysis

All results were expressed as Mean ± S.D. Student 't' test was performed.

RESULTS

In the present study, preliminary phytochemical screening of the *Musa sapientum* powder extract in different solvents like ethanol, methanol, chloroform, benzene, ethyl acetate and water was carried out. Of these the ethanolic, methanolic and ethyl acetate extracts showed better results of phytoconstituents than other solvents. The methanolic extract of *Musa sapientum* was subjected to High-Performance Thin-Layer Chromatography (HPTLC) Technique. The plate was visualized at 254 nm, 366 nm and scanned at 254 nm. The analysis of retention factor and colors of the resolved bands indicated the presence of a flavonoid at R_f 0.71 which may be leucocyanidin

[Figure 1a, 1b and 1c] by comparing with the peak of authenticated standard leucocyanidin [Figure 1d].

There was a significant decrease in the body weight (100%) in the ulcer induced group when compared to normal. Treatment with herbal drug of *Musa sapientum* (200%) and standard antiulcer drug esomeprazole (57%) showed a significant weight gain.

There was increase in the gastric volume (160.33%), ($P < 0.001$) and decrease in pH (51.61%), ($P < 0.001$) in the indomethacin administered group. On administration of *Musa sapientum* and esomeprazole, the level of gastric volume was significantly reduced (46.03%, 34.92%) and the pH was increased (93.33%, 76.66%) when compared to indomethacin-induced rats [Table 1].

The count of WBC of indomethacin administered group was significantly increased (81.55%) when compared to

normal and moderate (32.38%) to mild (13.10%) decrease in count was observed in *Musa sapientum* and esomeprazole treated groups respectively. The level of hemoglobin in the indomethacin administered group was significantly decreased (48.01%) when compared to normal and a significant (65.07%) to moderate (50%) increase in the level of hemoglobin was observed in *Musa sapientum* and esomeprazole treated groups respectively [Table 2].

The gastric mucosal protein was significantly reduced (41.33%) in ulcerated rats when compared to normal. Treatment with *Musa sapientum* and esomeprazole significantly increased (60%, 41.81%) the mucosal protein when compared to the indomethacin administered group of animals. The gastric mucosal sialic acid was also significantly reduced (45.80%) in ulcerated rats when compared to normal. Treatment with *Musa sapientum* and esomeprazole significantly increased (62.34%, 42.25%) the mucosal sialic acid in indomethacin-induced ulcerated rats. Also, the level of mucosal hexosamine was significantly reduced (18%) in ulcerated rats when compared to normal. Treatment with *Musa sapientum* and esomeprazole significantly increased (13.4%, 11%) the mucosal hexosamine in indomethacin-induced ulcerated rats.

The nitric oxide in the gastric mucosal tissues was significantly decreased (27.84%) in ulcerated rats when compared to normal. Treatment with *Musa sapientum* and esomeprazole significantly increased (34.96%, 24.06%) the mucosal tissue nitric oxide in indomethacin-induced ulcerated rats. The nitric oxide in the serum was significantly increased (45%) in ulcerated rats when compared to normal. Treatment with *Musa sapientum* and esomeprazole significantly decreased (26.79%, 20.68%) the nitric oxide in the serum in indomethacin-induced ulcerated rats [Table 3].

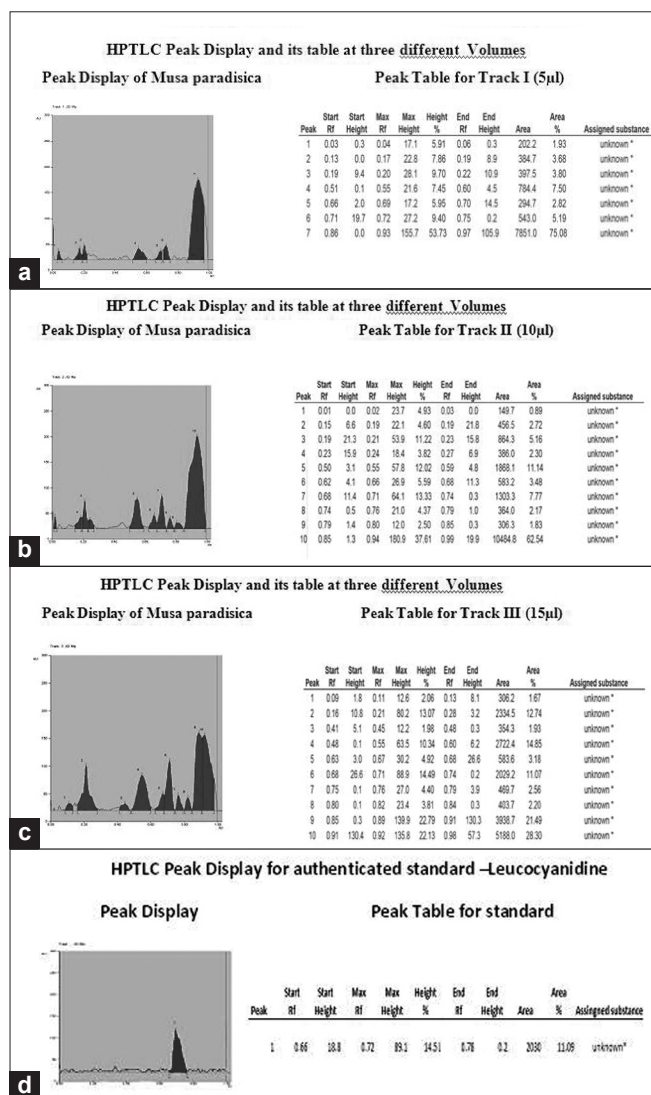


Figure 1: HPTLC Peak Display and its table at three different volumes

DISCUSSION

Peptic ulcer is a common disorder of the gastrointestinal tract.^[19] Antiulcer drugs are associated with severe side-effects.^[20] Clinical research has confirmed the efficacy of several plants for the treatment of gastroduodenal diseases.^[21] Preliminary phytochemical screening of unripe plantain banana (*Musa sapientum*) revealed the presence of primary

Table 1: Profile of gastric juice

Parameters	Group I	Group II	Group III	Group IV
pH	3.1 ± 0.28	1.5 ± 0.18 ^a	2.9 ± 0.29 ^{bc}	2.65 ± 0.2 ^{bd}
		(51.61%)	(93.33%)	(76.66%)
Volume	2.42 ± 0.29	6.3 ± 0.43 ^a	3.4 ± 0.21 ^{bd}	4.1 ± 0.21 ^{ca}
		(160.33%)	(46.03%)	(34.92%)

Values are means ± S.D n = 6, ^aGroup I vs. Group II, ^{bc}Group II vs. Group III, IV, ^a $P < 0.001$; ^b $P < 0.05$; ^cnot significant

Table 2: Effect drugs on blood cells and hemoglobin in ulcerated rats.

Parameters	Group I	Group II	Group III	Group IV
Total WBC count per cu mm	5150 ± 341.5	9350 ± 369.68 ^a (81.55%)	6322 ± 291.01 ^{ab} (32.38%)	8125 ± 1854 ^{aa} (13.10%)
Hemoglobin (g/dl)	12.12 ± 0.50	6.3 ± 0.25 ^a (48.01%)	10.4 ± 0.25 ^{aa} (65.07%)	9.45 ± 0.25 ^{aaa} (50%)

Values are means ± S.D n = 6, ^aGroup I vs. Group II, ^{aa}Group II vs. Group III, IV, ^a-P < 0.001; ^b-P < 0.05

Table 3: Effect of drugs on gastric mucosal profile in ulcerated rats

Parameters	Group I	Group II	Group III	Group IV
Mucosal Protein (g/dl)	3.75 ± 0.91	2.2 ± 0.31 ^a (41.33)	3.52 ± 0.29 ^{bc} (60)	3.12 ± 0.49 ^{ab} (41.81)
Sialic Acid µg/100 mg of Tissue	110.25 ± 7.80	59.75 ± 7.27 ^a (45.80)	97 ± 6.16 ^{ab} (62.34)	85 ± 2.94 ^{ab} (42.25)
Hexosamine µg/100mg of Tissue	1730 ± 45.61	1419.25 ± 26.28 ^a (18)	1610 ± 11.5 ^{ab} (13.4)	1575 ± 13.34 ^{ab} (11)
No (Tissue) µ mol/l	305.25 ± 5.43	220.25 ± 5.85 ^a (27.84)	297.25 ± 5.56 ^{bc} (34.96)	273.25 ± 12.36 ^{aa} (24.06)
No (serum) µ mol/l	65 ± 2.58	94.25 ± 3.20 ^a (45)	69 ± 1.63 ^{bc} (26.79)	74.75 ± 2.5 ^{ab} (20.68)

Values are means ± S.D n = 6, ^aGroup I vs. Group II, ^{aa}Group II vs. Group III, IV, ^a-P < 0.001; ^b-P < 0.05; ^c-not significant, figures in parentheses indicates in percentage.

and secondary metabolites. Screening of active compound using HPTLC revealed the presence of a monomeric flavonoid Leucocyanidin.

Studies by David *et al.*,^[22] reported that Leucocyanidin and its synthetic hydroxyl ethylated and tetra allyl derivatives were found to protect the gastric mucosa from aspirin-induced erosions. Leucocyanidin and its hydroxyl ethylated and tetra allyl derivatives significantly increased mucus thickness.

The mechanism by which indomethacin induces ulcer is by inducing H⁺/ K⁺ ATPase in gastric parietal cells. This increases the gastric acid secretion and decreases pH in ulcerated rats, whereas esomeprazole, a PPI (proton pump inhibitor) inhibits H⁺/ K⁺ ATPase in gastric parietal cells.^[23] In our present study the decrease in gastric volume and increase in pH in *Musa sapientum*-treated animals might be by inhibiting the HCl secretion. Amr *et al.*,^[24] in their studies reported that there was significant decrease in gastric volume and increase in pH when the ulcerated rats were treated with Cinnamon and Chamomile in dose-dependent manner. Our results are comparable with their report. The decrease in the level of hemoglobin might be due to internal bleeding in the lesions of the gastrointestinal (GI) tract and increase in the count of WBC might be the function of immune cells against the inflammation in ulcerated rats. In *Musa sapientum*-treated animals the results were reversed which might be due to the presence of a flavonoid leucocyanidin, a compound which protects the gastrointestinal mucosa from lesions produced by various drugs like NSAIDs and other ulcerogenic agents, and was in agreement with the results of standard drug esomeprazole. Green unripe plantains have been reported to have an active principle(s) which enhances the formation of red blood cells in addition to the gastro-protective capacity

against indomethacin-induced gastric mucosal injury in rats.^[25] David *et al.*,^[26] in their study stated that dried unripe plantain banana powder, leucocyanidin extracted from *Musa sapientum* and a purified synthetic leucocyanidin have a protective effect against aspirin-induced erosions. Our results are in agreement with their report.

The decrease in the protein content of the gastric mucosa in the indomethacin administered groups may be due to damage in the gastric mucosa which results, in the leakage of protein into the gastric juice. Treatment with *Musa sapientum* increased the mucosal protein which indicates its ability to act at the cellular level in the mucus gland, i.e. it enhances cell proliferation and stimulates the growth of the gastric mucosa. This stimulatory effect of banana on mucosal growth was responsible for the rapid healing of ulcers in rats treated with indomethacin and was congruent with the results of esomeprazole. *Musa sapientum* increases mucus resistance to ulcerogenic substances thus enhanced the recovery from ulcers.^[10]

There was a significant decrease in the levels of glycoproteins, viz. sialic acid and hexosamine, of the gastric mucosa in the ulcerated group of rats when compared to normal groups which might be due to damage in the mucosal layer. On treatment with antiulcer standard drugs (esomeprazole) and *Musa sapientum*, there was significant elevation in the level of sialic acid and hexosamine when compared to the ulcer-induced group. The mechanism of action of *Musa sapientum* is by stimulating the growth of the gastric mucosa by increasing mucosal protein i.e. sialic acid and hexosamine, which in turn increase the production of mucus and thus prevent erosion by the ulcer. These significant increased levels of sialic acid and hexosamine correlated with the increased mass of mucosa in the stomach of animals treated with banana. The mode of action of the banana

appears to be unlike that of conventional anti-ulcerogenic drugs in that it promotes mucus secretion by stimulating the growth of mucosal cells. The regenerated mucosa cells would rapidly seal damaged areas with a secretory layer of mucus and prevent further erosions due to gastric HCl and pepsin.^[6]

The beneficial effect of the administration of dried banana powder might be due to its enhanced mucosal resistance. *Musa sapientum* also promotes healing of ulcers by the presence of water-soluble polysaccharides (e.g. Pectin) in unripe plantain banana.^[27]

The level of NO was significantly elevated in the serum in ulcerated rats when compared to normal rats. Administration of *Musa sapientum* and antiulcer drugs decreases the level of NO in serum when compared to ulcerated rats. The level of NO in tissue was significantly reduced when compared to normal whereas treatment with *Musa sapientum* and antiulcer drugs brought the level of NO in tissue to near normal.

Nishida *et al.*,^[28] in their study reported that NO produced by Constitutive Nitric Oxide Synthase (cNOS) is cytoprotective and NO produced by inducible nitric oxide synthase (iNOS) is cytotoxic. Tarek *et al.*,^[29] in their study reported that the ulcerated rats exhibited marked reduction in tissue NO, which further adds to the enhanced neutrophil infiltration. It was reported that indomethacin caused up-regulation of endothelin-1^[30] that leads to decreased production of gastric mucosal cNOS. In addition, the neutrophil-derived HOCl was reported to inhibit cytoprotective eNOS.^[31] On the contrary, the study by Tarek *et al.*,^[29] demonstrated that indomethacin produced a marked elevation in serum NO, the observed increase in myeloperoxidase (MPO) activity may facilitate the increase in serum NO as the MPO/H₂O₂ system serves as a major catalytic sink for NO preventing NO feedback inhibition.^[32] Tarek *et al.*,^[29] in their results reported that indomethacin-induced gastric injury might be mediated, at least in part, by the reduction in tissue cNOS-derived NO content and enhanced production of iNOS-derived NO in serum. Our findings concerning NO are in agreement with the widely accepted fact that, in the digestive system, NO produced by cNOS is cytoprotective and NO produced by iNOS is cytotoxic.

The antiulcer property of herbal plants has been studied and reported by many ethnobotanists.^[33-36] But studies by Ratnasooriya^[37] and Arambewela *et al.*,^[38] reported that even nutraceutical products like black tea and the ginger family have antiulcer property.

Vimal *et al.*,^[39] in their studies with polyherbal drugs with

the composition of *Asparagus racemosus* Wild (AR), *Centella asiatica* Linn (CA), *Convolvulus pluricaulis* (CP), *Embllica officinalis* (EO), *Ocimum sanctum* (OS) and *Withania somnifera* Dunal (WS), reported that the polyphenols, flavonoids etc., present in these plants have antiulcer activity. The possible mechanism of antiulcer activity may be by the presence of polyphenols in poly herbal drug which inhibited acetylcholine synthesis. Free radicals are involved in the progression of ulcers. Extract from *Cassia auriculata* possesses maximum *in vitro* free radical scavenging activity along with an ameliorative effect on various ulcerative parameters.^[40]

Musa sapientum being a nutraceutical, can be consumed as food rather than as a drug which enhances the satiety value for the patients.

CONCLUSION

Our results showed protective effects against indomethacin-induced gastric erosions in animal models by *Musa sapientum* as shown by the absence of mucosal damage at the dosage of 100 mg/kg/ day. The active components such as leucocyanidin may be responsible for the antiulcer properties and protect the mucosa by stimulation of cell proliferation, promoting mucus secretion, increasing mucus resistance, inhibiting the HCl secretion and thus healing the ulcer.

REFERENCES

1. Bhattacharjee M, Bhattacharjee S, Gupta A, Banerjee RK. Critical role of an endogenous gastric peroxidase in controlling oxidative damage in *H. pylori*-mediated and non-mediated gastric ulcer. *Free Radical Biol Med* 2002;3:731-43.
2. Bandyopadhyay D, Biswas K, Bhattacharyya M, Reiter RJ, Banerjee RK. Gastric toxicity and mucosal ulceration induced by oxygen-derived reactive species, protection by melatonin. *Curr Mol Med* 2001;1:501-13.
3. Rao CH, Ojha SK, Radhakrishnan K, Govindarajan R, Rastogi S, Mehrotra S, *et al.* Antiulcer activity of *Utleria salicifolia* rhizome extract. *J Ethnopharmacol* 2004;91:243-9.
4. Bandyopadhyay D, Biswas K, Bhattacharyya M, Reiter RJ, Banerjee RK. Involvement of reactive oxygen species in gastric ulceration, protection by melatonin. *Indian J Exp Biol* 2002;40:693-705.
5. Czinner E, Hagymas K, Blazovics A, Kery A, Szoke E, Lemberkovics E. The *in vitro* effect of *Helichysi flos* on microsomal lipid peroxidation. *J Ethnopharmacol* 2001;77:31-5.
6. Best R, Lewis DA, Nasser. The anti-ulcerogenic activity of the unripe plantain banana (*Musa* species). *Br J Pharmacol* 1984;82:107-16.
7. Dunijic BS, Svensson J, Axelson J, Adler Creutz P, Bengmark S. Green banana protection of gastric mucosa against experimentally induced injuries in rats a multi component mechanism. *Scand J Gastroenterol* 1993;28:894-8.
8. Valliathan MS. Healing plants. *Curr Sci* 1998;5:1122-6.

9. Dey B, Sita Raman MV. Laboratory Manual of Organic Chemistry. Chennai: S. Viswanathan Publication; 1957
10. Goel RK, Gupta S, Shankar R, Sanyal AK. Anti Ulcerogenic Effect of banana powder (*Musa sapientum* Var. *Paradisica*) and its effects on mucosal resistance. J Ethnopharmacol (IRL) 1986;18:33-44.
11. Whittle BJ. Relationship between the prevention of rat gastric erosions and the inhibition of acid secretion by prostaglandins. Eur J Pharmacol 1976;40:233-9.
12. Scheiman JM, Yeomans ND, Talley NJ, Vakil N, Chan FK, Tulassay Z, et al. Prevention of ulcers by esomeprazole in at-risk patients using non-selective NSAIDs and COX-2 inhibitors. Am J Gastroenterol 2006;101:711-3.
13. Carman RH. Hand book of Medical Laboratory Technology. 2nd Ed, Pub Chritian Medical Association 1993. p. 121-2.
14. Schmidt HHW. Determination of nitric oxide via measurement of nitrite and nitrate. Biochemica 1995;2:22-3.
15. Wagner WD. A more Sensitive Assay discriminating galactosamine and glycosamine in mixture. Ana Biochem 1979;94:349-96.
16. Lowry OH, Rose Brough MH, Farr L, Randell RM. Protein Measurement with the folin phenol reagent. J Biol Chem 1951;93:265-75.
17. Winzler RJ. Determinations of serum glycoprotein, Methods of biochemical analysis. Vol 2. In: Glick D, editor. New York, USA: Inter Science Publishers; 1955. p. 279-311.
18. Shay JP, Komoru SA, Fells SS, Meranze D, Grunstein M, Simpler H. A simple method of uniform production of gastric ulceration in rats. Gastroenterology 1945;5:43.
19. Mayty P. Studies focused merely on a single oxygen species through the induction of cytochrome. Smoking and pathogenesis of gastroduodenal ulcer- recent machanistic update 2003;97:450.
20. Bandyopadhyay S. Miscellaneous notes on *Bauhinia* L. (Leguminosae: Caesalpinioideae) - II. J Econ Taxon Bot 2001;25:10-2.
21. Gurubuz K, Kucukkardali Y, Yazgan Y, Ozel M, Polat T. Does eradication of *Helicobacter pylori* infection reduce hypergastrinemia during long term therapy with proton pump inhibitors. Ulhane military medical academy, Haydarpasa Training Hospital Department of Gastroenterology and Internal medicine, Istanbul. Turke: 2000.
22. Lewis DA, Shawb GP. A natural flavonoid and synthetic analogues protect the gastric mucosa from aspirin-induced erosions. J Nutr Biochem 2001;12:95-100.
23. Kobayashi T, Yokoyama I, Suzuki A, Abe M, Hayashi S, Matsuda H, et al. Lack of antibody Production against Hanganutziu-Deicher (H-D) antigens with N-glycolyneuraminic acid in patients with porcine exposure history. Xenotransplantation 2000;7:177-80.
24. Rezaq AA, Elmallh MM. Anti-ulcer effect of cinnamon and chamomile aqueous extracts in rat. Models J Am Sci 2010;6:209-11.
25. Arora A, Sharma MP. Use of banana in non-ulcer dyspepsia. Lancet 1990;435:612-3.
26. Lewis DA, Fields WN, Shaw GP. A natural flavonoid present in unripe plantain banana pulp (*Musa sapientum* L. var. *paradisica*) protects the gastric mucosa from aspirin-induced erosions. J Ethnopharmacol 1999;65:283-8.
27. Mayberrayn DJ, Rhoder F, Howellsn B, Malthewsi, Agglutinins to anaerobic bacteria in Crohn's disease and in India patients with diarrhoea. The pathological society of Great Britain and Ireland; 1981.
28. Nishida K, Ohta Y, Ishiguro I. Contribution of NO synthases to neutrophil infiltration in the gastric mucosal lesions in rats with water immersion restraint stress. FEBS Lett 1998;425:243-8.
29. Motawi TK, Abd Elgawad HM, Shahin NN. Gastroprotective effect of leptin in indomethacin - induced gastric injury. J Biomed Sci 2008;15:405-12.
30. Slomiany BL, Slomiany A. Role of endothelin-converting enzyme-1 in the suppression of constitutive nitric oxide synthase in rat gastric mucosal injury by indomethacin. Scand J Gastroenterol 2000;35:1131-6.
31. McCarty MF. The reported clinical utility of taurine in ischemic disorders may reflect a down-regulation of neutrophils activation and adhesion. Med Hypotheses 1999;53:290-9.
32. Galijasevic S, Saed GM, Diamond MP, Abu-Soud HM. Myeloperoxidase up-regulates the catalytic activity of inducible nitric oxide synthase by preventing nitric oxide feedback inhibition. Proc Natl Acad Sci USA 2003;100:14766-71.
33. Jain A, Surana S. Antiulcerogenic effects of *Gymnosporia rothiana* (Celastraceae) against different experimental models. Phcog Mag 2009;5:100-4.
34. Purushothaman M, Dhanapal R, Balakrishnan M, Srinivasan S, Anbarasu C, Sriram R. Phytochemical and anti-ulcer investigations of the whole plant extract of *Neregamia alata* wight and Arn. in albino rat model. Phcog Mag 2009;5:19-22.
35. Jainu M, Vijaimohan K, Kannan K. *Cissus quadrangularis* L. extract attenuates chronic ulcer by possible involvement of polyamines and proliferating cell nuclear antigen. Phcog Mag 2010;6:225-33.
36. Niazmand S, Khooshnood E, Derakhshan M. Effects of *Achillea wilhelmsii* on rat's gastric acid output at basal, vagotomized, and vagal-stimulated conditions. Phcog Mag 2010;6:282-5.
37. Ratnasooriya W, Fernando T. Gastric ulcer healing activity of Sri Lankan black tea (*Camellia sinensis* L.) in rats. Phcog Mag 2009;5:260-5.
38. Arambewela L, Arawwawala L, Ratnasooriya W. Effect of *Alpinia calcarata* rhizomes on ethanol - induced gastric ulcers in rats. Phcog Mag 2009;5:226-31.
39. Vimal SK, Sharma D, Bhatnagar M. Anti-bacterial activity of herbal extracts, EuMil[®] and antibiotics against *Helicobacter muridarum*. Phcog J 2010;2:436-41.
40. Ahmed M, Rao SA, Thayyil HA, Ahemad RS, Abid M, Ibrahim M. Anti-ulcer activity of *Cassia auriculata* leaf extract. Pharmacog J 2010;2:48-52.

Cite this article as: Prabha P, Karpagam T, Varalakshmi B, Sohna Chandra Packiavathy A. Indigenous anti-ulcer activity of *Musa sapientum* on peptic ulcer. Phcog Res 2011;3:232-8.

Source of Support: Nil, **Conflict of Interest:** None declared.