

# Additive Effects of High Fructose Corn Syrup (HFCS) in Experimental Oral Carcinogenesis

Kavitha Kalimuthu<sup>1</sup>, Sindhu Ganapathy<sup>1,2,\*</sup>, Balamurugan Elumalai<sup>1</sup>, Asha Kumarasampillai Radha Thayammal<sup>3</sup>, Veeran Veeravarmal<sup>4</sup>, Vijayalakshmi Annamalai<sup>5</sup>

<sup>1</sup>Department of Biochemistry and Biotechnology, Faculty of Science, Annamalai University, Annamalai Nagar, Chidambaram, Tamil Nadu, INDIA.

<sup>2</sup>Department of Biochemistry, Government Arts College (Autonomous), Kumbakonam, Tamil Nadu, INDIA.

<sup>3</sup>Department of Biochemistry, Government Arts College, Paramakudi, Tamil Nadu, INDIA.

<sup>4</sup>Department of Oral and Maxillofacial Pathology, Rajah Muthiah Dental College and Hospital, Annamalai Nagar, Tamil Nadu, INDIA.

<sup>5</sup>Plant Head, Galileovan Offshore and Research and Development Private Limited, Nagapattinam, Tamil Nadu, INDIA.

## ABSTRACT

**Introduction:** Nowadays, fructose uses dramatically increased in form of High-Fructose Corn Syrup (HFCS) found in juices and packed food. Sustained fructose utilization is detrimental to long-term human health. **Objectives:** To assess the additive effects of HFCS during 7,12-Dimethylbenz(a)Anthracene (DMBA)-induced Hamster Buccal Pouch Carcinogenesis (HBPCs) model. **Materials and Methods:** The animals were separated into eight groups: Group I; vehicle control; Group II (0.5% DMBA); Group III and IV (HFCS 8% and 25%); Group V (Sucrose 10%); Group VI and VII (0.5% DMBA+HFCS 8 and 25%) and VIII group (0.5% DMBA+Sucrose 10%) respectively for 14 weeks. After the 14<sup>th</sup> week of treatment; the tumor morphology, buccal histopathology, and biochemical markers were measured and compared with carcinogenic control as well as vehicle control. **Observations and Results:** The buccal pouch of golden Syrian hamsters developed well-differentiated squamous cell carcinoma after getting topical applications of 0.5% DMBA in liquid paraffin three times a week for 14 weeks. Although DMBA treatment alone caused 100% tumor development in hamsters, drinking water administration of HFCS at a concentration of 25%/kg body weight (b.w.) to DMBA-treated hamster greatly accelerated the development of oral tumors. Additionally, during DMBA-induced oral carcinogenesis, HFCS moderately increased the lipid peroxidation by-products, decreased the status of enzymatic and non-enzymatic antioxidants, modulated the levels of phase I and phase II detoxification agents, and favored the excretion of carcinogenic metabolite. **Conclusion:** The present study concludes that the additive effect of HFCS relies on its altered peroxidative and antioxidant function as well as effects on phase I and II detoxification enzymes during DMBA-induced hamster buccal pouch carcinogenesis. Taken together the current study described that HFCS induced oral tumour development. From this study we suggested HFCS usage to be curtailed.

**Keywords:** DMBA, Oral cancer, Hamsters, HFCS, Detoxification enzymes, Lipid peroxidation, Antioxidants.

## Correspondence:

**Dr. Ganapathy Sindhu**

Assistant Professor, Department of Biochemistry and Biotechnology, Faculty of Science, Annamalai University, Annamalai Nagar-608002, Chidambaram, Tamil Nadu, INDIA.

Email: ganapathysindhu@gmail.com

**Received:** 21-06-2023;

**Revised:** 14-07-2023;

**Accepted:** 09-08-2023.

## INTRODUCTION

The largest prevalence of oral cancer are seen in South and Southeast Asia (such as Sri Lanka, India, and Taiwan), where it ranks as the eleventh most prevalent cancer globally.<sup>[1]</sup> The survival rate for oral cancer at five years is still around 50%.<sup>[2]</sup> The proportion of patients with advanced disease has not changed over the past 40 years.<sup>[3]</sup> Despite efforts in public education and screening, it is anticipated around 10 to 35% of occasions result in the formation of a second main tumor. The majority of head

and neck cancers, which have an incidence of around 630,000 new cases each year worldwide and nearly 10,000 annual deaths in the United States, are squamous cell carcinomas.<sup>[4,5]</sup> The most common risk factors for HNSCC includes unhealthy habits like drinking alcohol, using tobacco products, and chewing betel nut.<sup>[6]</sup>

Chemical carcinogen 7,12-Dimethyl Benzantracene (DMBA) induces carcinogenesis in oral cancer tissue.<sup>[7]</sup> Oral tissue injury is correlated with DMBA and abnormal cell division.<sup>[8]</sup> Researchers can investigate the mechanisms of mouth cancer using animal models, particularly hamsters.<sup>[9]</sup>

Compared to the 19<sup>th</sup> century, fructose intake increased in the 21<sup>st</sup> century.<sup>[10]</sup> Despite the fact that high fructose consumption led to metabolic conditions such obesity and



DOI: 10.5530/pres.15.4.087

### Copyright Information :

Copyright Author (s) 2023 Distributed under Creative Commons CC-BY 4.0

Publishing Partner : EManuscript Tech. [www.emanuscript.in]

insulin resistance.<sup>[11]</sup> It might lead to the growth of tumors and encourage carcinogenesis.<sup>[12]</sup> Fructose promotes the generation of acinar-cell tumor nodules in the pancreas tissue treated with N-nitrosomorpholine and can introduce alternative carbohydrate substrate for pancreatic cancer growth.<sup>[13,14]</sup> A commercial sugar addition called HFCS is utilized in processed foods and beverages because of its potent sweetening effect and low cost.<sup>[15]</sup>

Consumption of high fructose foods and beverages has increased recently, and this eating habits has been linked to an increase in a variety of chronic diseases. Consumption of HFCS and high fructose corn syrup raises the chance of developing some potentially fatal cancers.<sup>[16]</sup> Further research may reveal that consumption of fructose exceeding confidential comes out is followed by tissue conditions.<sup>[17]</sup> Liu and Heaney reported that Consuming excessive fructose alters cellular metabolism, produces more reactive oxygen species, damages DNA, and causes inflammation, which all contribute to the growth of cancer. Cancer cells utilize fructose for proliferation and nucleic acid production.<sup>[18]</sup> According to Coussens *et al.*, the environment for the development of malignancy is made more favorable by the overexpression of inflammatory response mediators and angiogenesis, and the development of cancer with enhanced production of inflammatory cells has been documented.<sup>[19]</sup>

In the present study we hypothesized that HFCS had additive effects during DMBA induced HBPCs. Tumor morphology, buccal histology, and biochemical markers such as LPOs and the status of enzymatic and nonenzymatic antioxidants as well as the levels of phase I and phase II detoxification agents, and execution of apoptosis were measured to find additive effects of HFCS during DMBA-induced oral carcinogenesis.

## MATERIALS AND METHODS

### Experimental Animals

*Mesocricetus auratus* (golden Syrian hamsters) 8-10 weeks old (80-120 g) Male, 48 numbers, proposed source of animal were procured from Biogen, Animal Laboratory House, Bangalore and maintained at Central Animal House, K M College of Pharmacy, Madurai. The animals were acclimatized for 1 week prior to the experiment and then randomized into 8 groups with six animals in each group. The Committee for the Purpose of Control and Supervision of Experiments on Animals (CPCSEA-Proposal no IAEC/K.KAVITHA/AU/PhD/KMCP/161/2022-23), Ministry of Environment, Forests and Climate Change, Government of India, provided the guidelines for all animal quarantine and experimental procedures. The animals are kept in polypropylene cages and fed a standard pellet diet (carbohydrate 48.8%, protein 21%, and fat 3%, calcium 0.8%, phosphorus 0.4%, fiber 5%, moisture 13%, and ash 8%). Mysore snacks feed Ltd, Mysore, India, water without restriction, and regulate temperature and humidity using an oscillating cycle of light and dark.

### Tumor induction

Buccal pouch carcinogenesis induced in male golden Syrian hamsters in the left buccal pouch using 0.5% DMBA in liquid paraffin three times per week for 12 weeks by using the No. 4 painting brush.

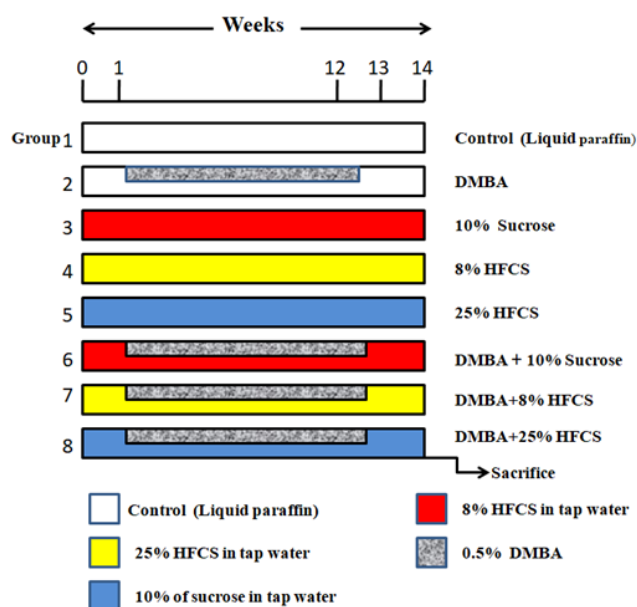
### HFCS preparation

The HFCS dissolved in tap water as 8% and 25% per kg body weight respectively and each hamster administered through water bottles as water *ad libitum*. 10% Sucrose also prepared in the same way in tap water and each hamster administered through water bottles as water *ad libitum*.

### Experimental design

48 animals were divided into eight groups ( $n=6$ ) to evaluate the effect of HFCS on oral carcinogenesis by cellular and molecular studies.: Group I; Vehicle control (the animals were painted using liquid paraffin); Group II (0.5% DMBA); Group III and IV (HFCS 8% and 25%); Group V (Sucrose 10%); Group VI and VII (0.5% DMBA+HFCS 8% and 25%) and VIII group (0.5% DMBA+Sucrose 10%) respectively for 12 weeks. Tumor morphology, buccal histology, and biochemical markers were assessed after the 14<sup>th</sup> week of treatment. The left buccal pouch of hamsters was treated with 0.5% DMBA in liquid paraffin using a no. 4 brush three times per week for a period of twelve weeks. HFCS was provided in the study's water supply. The experimental layout is depicted in Figure 1.

Animal will be sacrificed by over dose of ketamine, 24 hr after the end of treatment. Blood was collected through intra orbital sinus puncture from each hamster and were centrifuged at 3000 rpm for 15 min. The serum were collected and stored at



**Figure 1:** Schematic illustration of the experimental design.

DMBA; 7,12-dimethylbenz(a)anthracene, HFCS-High fructose corn syrup.

–20°C for biochemical analysis. Liver and Buccal pouches were removed and processed for the preparation of homogenates and histological studies. To determine the animal's body weight; the starting and final weights were subtracted. It was determined how many tumors there were overall in the HBP. Volume of the tumor was measured using the formula  $V = \frac{4}{3}\pi (D_1/2) \cdot (D_2/2) \cdot (D_3/2)$ , in which  $D_1$ ,  $D_2$ , and  $D_3$  are the three diameters ( $\text{mm}^3$ ) of the tumor. The number of tumours per hamster was multiplied by the tumour volume to determine the tumour burden.

### Histological study

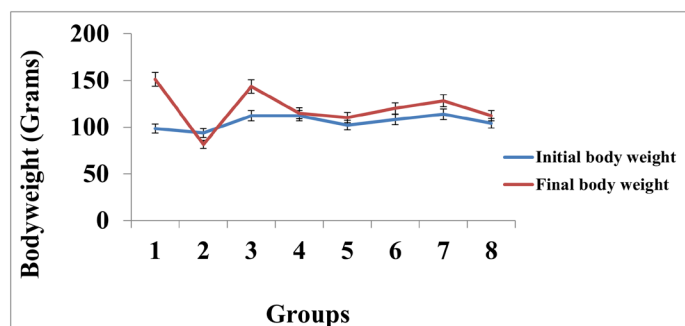
Buccal tissues were preserved in a 10% formalin solution, and then dried in ethanol that ranged from 50% to 100% before being covered in paraffin. On a revolving microtome, the 2-3 m pieces were cut and collected on clean, dried glass slides at 37°C. It had hematoxylin and eosin on it. These slides were examined under a microscope at 10X and 40X for histopathological pictures of OSCC.

### Biochemical analysis

The protein content was estimated by Lowry *et al.*,<sup>[20]</sup> method. The quantification methodology was used to quantify CD, LOOH and TBARS<sup>[21,22]</sup> respectively. The activity of SOD, GPx, and CAT were measured using methods created by respectively.<sup>[23-25]</sup> Using methods outlined by respectively, the levels of Vit-E and GSH.<sup>[26-29]</sup> in the plasma and buccal mucosa were measured. Cytochrome P450, Cytochrome b5, GSH and GR were measured by the method.<sup>[30]</sup>

### Enzyme-Linked Immunosorbent Assay (ELISA) estimation of caspase-3 and 9 activities

The apoptotic marker enzymes caspase-3 and 9 have been examined in the buccal mucosa using the ELISA assay kit. The findings are supported by the spectrophotometric detection of the chromophore pNA, which is detected at 405 nm using microplate reader as the result of the cleavage of the labelled substrates caspase-3 substrate DEVDpNA and caspase-9 substrate LEHD-pNA.



**Figure 2:** Body weight of hamsters used in the experimental and control groups.

Values are presented as the mean SD for each set of six hamsters. At  $p < 0.05$  (DMRT), values that do not have the same superscript letter differ significantly.

### Statistical analysis

In SPSS version 17.0 for Windows, the data were compared using one-way Analysis of Variance (ANOVA) and Duncan's Multiple Range Test (DMRT). Data is presented as mean SD. (SPSS Inc., Chicago, IL).

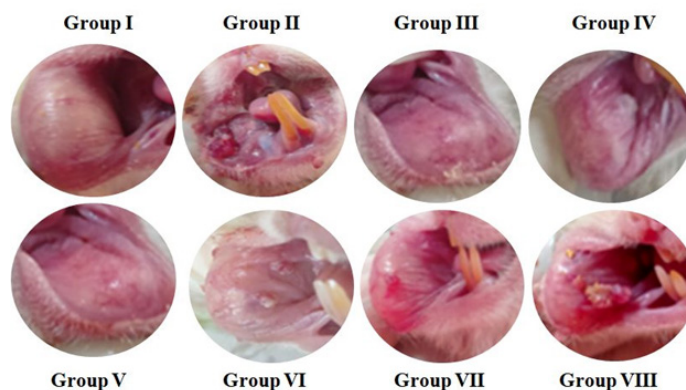
## RESULTS

### Effect of HFCS on body weight changes in Oral cancer hamsters

The differences in body weight measurements were noted in control and experimental hamsters are shown in Figure 2 at the beginning and end of each stage. As compare to group 1 hamsters, the level of body weight were considerably ( $p < 0.05$ ) lower in group 2 hamsters. For group 6, 7 and 8 DMBA painted plus HFCS drank hamsters at various doses of 10% sucrose, 8% and 25%/kg b.w. resulted a decrease in body weight that was substantial ( $p < 0.05$ ). For group 3, 4 and 5 hamsters with water intake of 10% sucrose, HFCS 8% and 25%/kg b.w showed appreciable gain in body weight.

### Tumor burden, incidence, and volume

Table 1 described in hamsters painted with DMBA alone, we saw 100% tumour formation with mean tumour volume ( $175.05 \text{ mm}^3$ ) and tumour burden ( $1575.45 \text{ mm}^3$ ) (Group 2). DMBA plus sucrose 10%, HFCS (8% and 25%) fed hamsters in groups 6, 7, and 8 extensively ( $p < 0.05$ ) increased with the tumor occurrence, tumour volume ( $75.09$ ,  $125.05$  and  $158.05 \text{ mm}^3$ ) and tumour burden ( $525.63$ ,  $1125.45$  and  $1896.6 \text{ mm}^3$ ) respectively. In Control group, 10% sucrose and HFCS (8% and 25%) alone fed hamsters, no tumour was seen. At week 6, all DMBA-treated animals had a mucosal mucosa surface that was noticeably roughened, grainy, and occasionally had a white plaque-like lesion. Animals from the vehicle treated and untreated groups both had the same appearance in their cheek pouches. Compared to hamsters treated



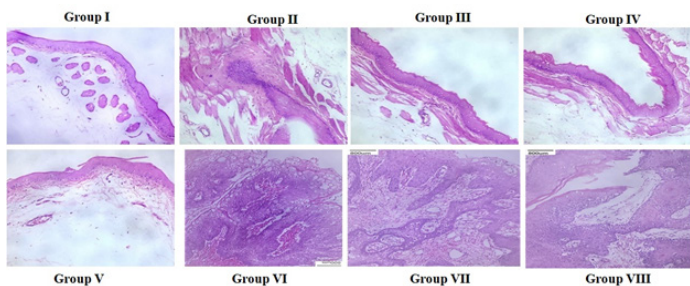
**Figure 3:** Photograph showing the gross appearance of oral tumors.

Buccal pouch mucosa of experimental and control animals ( $n=6$ ): gross appearance (40X). Group 2, 6, 7 and 8 Exophytic well-defined tumor mass in the hamster's buccal pouch at 14 and 16 weeks after being painted with DMBA and DMBA+HFCS (8 and 25%). Group 1 and 6 UMB alone and the normal buccal pouch in control

**Table 1: Shows the incidence, frequency, volume, and burden of tumors in experimental and control hamsters.**

Parameters	Control	DMBA	10% Sucrose	8% HFCS	25% HFCS	DMBA+10% Sucrose	DMBA + 8% HFCS	DMBA +25% HFCS
Tumor incidence	0	100%	0	0	0	100%	100%	100%
Total number of tumor/ hamsters	0	9 ± 0.69 <sup>b</sup>	0	0	0	7	9 ± 0.69 <sup>b</sup>	12 ± 0.69 <sup>b</sup>
Total volume (mm <sup>3</sup> )/ hamsters	0	175.05 ± 12.41 <sup>b</sup>	0	0	0	75.09 ± 08.21 <sup>b</sup>	125.05±11.81 <sup>b</sup>	158.05±13.41 <sup>b</sup>
Tumor burden (mm <sup>3</sup> )/ hamsters	0	1575.45 ± 120.65 <sup>b</sup>	0	0	0	525.63 ± 08.21 <sup>b</sup>	1125.45±120.65 <sup>b</sup>	1896.6±120.65 <sup>b</sup>

Values are presented as the mean SD for each set of six hamsters. Values with different superscript letters have a significant difference at  $p < 0.05$ .



**Figure 4:** Hematoxylin and eosin (10X) histopathological abnormalities in the buccal mucosa of experimental and control hamsters ( $n=6$ ) per group.

Photomicrograph of well-differentiated squamous cell carcinoma in DMBA alone, DMBA+sucrose, and DMBA+HFCS (8 and 25%) hamsters with larger cells, hyperchromatic nuclei, irregular edges, and pleomorphic. Control, sucrose, and HFCS alone hamster buccal pouch epithelium displayed typical squamous epithelium with no indication of cellular growth. Hamsters given HFCS 25% alone developed hyperkeratosis.

with DMBA alone, HFCS plus DMBA painting caused the tumor to appear 8 to 10 weeks earlier. However, tumor formation in DMBA-alone-induced hamsters took 10 to 12 weeks to manifest.

### Buccal mucosa's histological alterations

Figure 3 showed the gross appearance of oral tumours in hamsters with DMBA alone, HFCS plus DMBA and sucrose plus DMBA exposure. Table 2 shows the results of buccal mucosa tissues from control and test hamsters have been analysed histologically. Figure 4 have demonstrated that DMBA alone, sucrose with DMBA, and HFCS (8% and 25%) with DMBA all caused significant keratosis, hyperplasia, dysplasia, and well-differentiated squamous cell carcinoma in the buccal pouches of hamsters. Figure 4 b, e-h Further it is also shown as malignant tumor invasion and

the keratin pearl. Hyper keratosis was noticed in 25% HFCS alone treated hamsters Figure 4 c. Hamsters in group 1, 3 and 4 demonstrated a normal epithelium, no dysplastic stromal alterations, and no evidence of cell proliferation Figure 4a and c, d.

### Enzymatic antioxidants tests

Figures 5 and 6 is the buccal and Plasma of each group of experimental and control hamsters were examined for the presence of demonstrated a normal epithelium, no dysplastic stromal alterations, and no evidence of cell proliferation content in the hamsters administered DMBA alone, Sucrose 10% and HFCS (8% and 25%) with DMBA was noticeably ( $p \leq 0.05$ ) lower, with the exception of GPx (which increased in group 2, 6, 7 and 8). When uptake of Sucrose, HFCS (8% in drinking water) to hamsters in groups 3 and 4, current test were considerably ( $p < 0.05$ ) shown normal level compared to Group 1. But in HFCS 25% alone hamsters observed with altered activity.

### Non-enzymatic antioxidants tests

Figure 7 demonstrates the levels of non-enzymatic antioxidants (Vitamin E and GSH) in the blood and buccal mucosa of each group of control and experimental hamsters. Plasma non-enzymatic antioxidant levels significantly ( $p \leq 0.05$ ) reduced, although they increased in the buccal mucosa of the hamsters in group 2, 6, 7 and 8 who received DMBA alone compared to groups 1, 3 and 4, But in Hamster with 25% alone HFCS showed some changes in the level of current parameters. Both the buccal mucosa and plasma of hamsters treated with DMBA significantly ( $p < 0.05$ ) affects from non-enzymatic antioxidant status by HFCS drinking water uptake.



## Estimation of LPO

Figures 8 and 9 indicates the LPO markers amounts (TBARS, CD, and LOOH) in the buccal mucosa and plasma of experimental and control hamsters. All study groups' overall DMBA consumption levels varied significantly from one another. When compared, LPO by-product levels were significantly ( $p<0.05$ ) higher in the blood sample and lower in the considerable buccal tissues of DMBA, DMBA with HFCS hamsters (group 2). In the hamsters of groups 1, 3 and 4, no significant change was found. But HFCS 25% alone hamsters showed a change in the levels of LPO. From the data it indicates that HFCS shows negative effects on normal hamsters at high concentration.

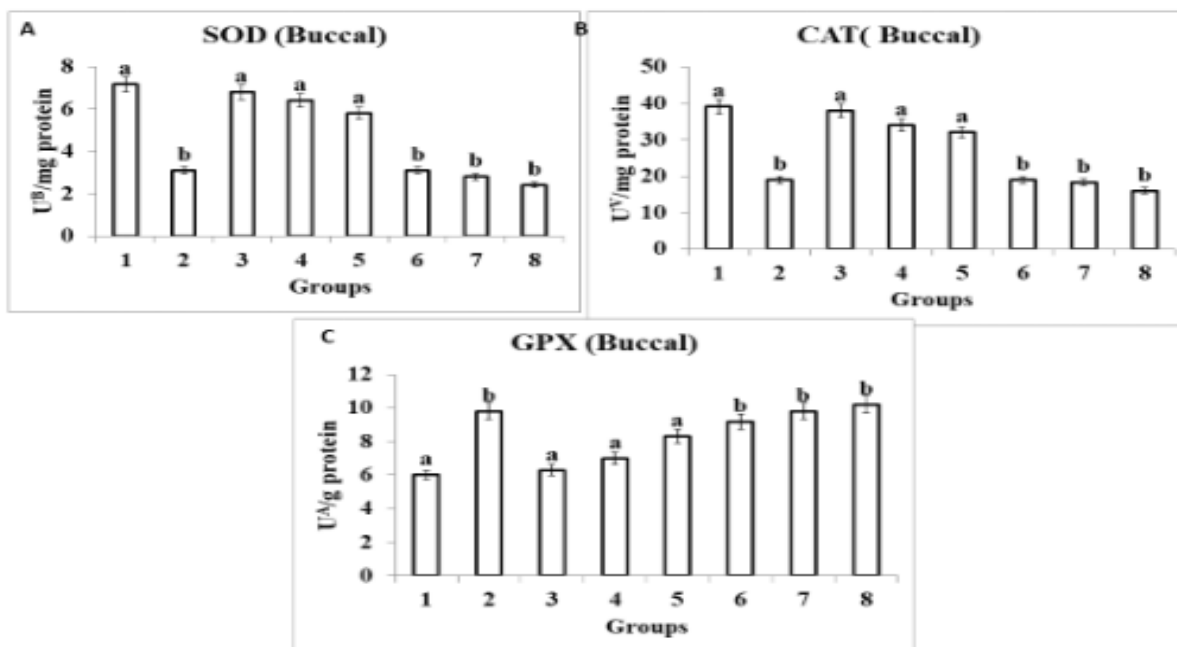
## Phase I and phase II biotransformation enzymes

In the oral tissue of experimental and control hamsters, Table 3 displays the concentrations of phase I (Cyt-p450 and Cytb5) and phase II (GST and GR) biotransformation enzymes. When DMBA and DMBA+HFCS hamsters were compared to control, it was

found that Phase II enzymes were significantly lowered ( $p<0.05$ ) while phase I enzymes were significantly enhanced ( $p<0.05$ ). In hamsters with sucrose and lower HFCS these activities were significant ( $p<0.05$ ) and declined back to nearly normal levels. But differences were found between hamsters treated to HFCS 25% alone. It indicates that HFCS were induced toxicity in liver by reduced their xenobiotic enzyme activities.

## Analysis of apoptotic markers in buccal region tissue by ELISA

Activities of the apoptotic marker enzyme caspase-3 and caspase-9 in experimental and control hamster buccal mucosa were seen in Figure 10. In Group 2, 6, 7 and 8, the caspase-3 and caspase-9 reactions were significantly ( $p\leq 0.05$ ) diminished. When compared to DMBA treated groups (2, 6, 7 and 8) in control, 10% sucrose, 8% and 25% HFCS alone treated hamsters the status of the aforementioned markers was noticeably ( $p\leq 0.05$ ) shifted towards the usual range.



**Figure 5:** Shows the buccal tissue levels of enzymatic antioxidants in the experimental and control groups of hamsters.

The mean SD for the six animals in each group is given as bars. Values that do not belong to the same group as a common superscript letter have a different significance (a and b).

a significantly different from group 6, 7 and 8; b significantly different from group 3, 4 and 5 (DMRT).

**Table 2: Buccal mucosal histopathological alterations in experimental and control hamsters.**

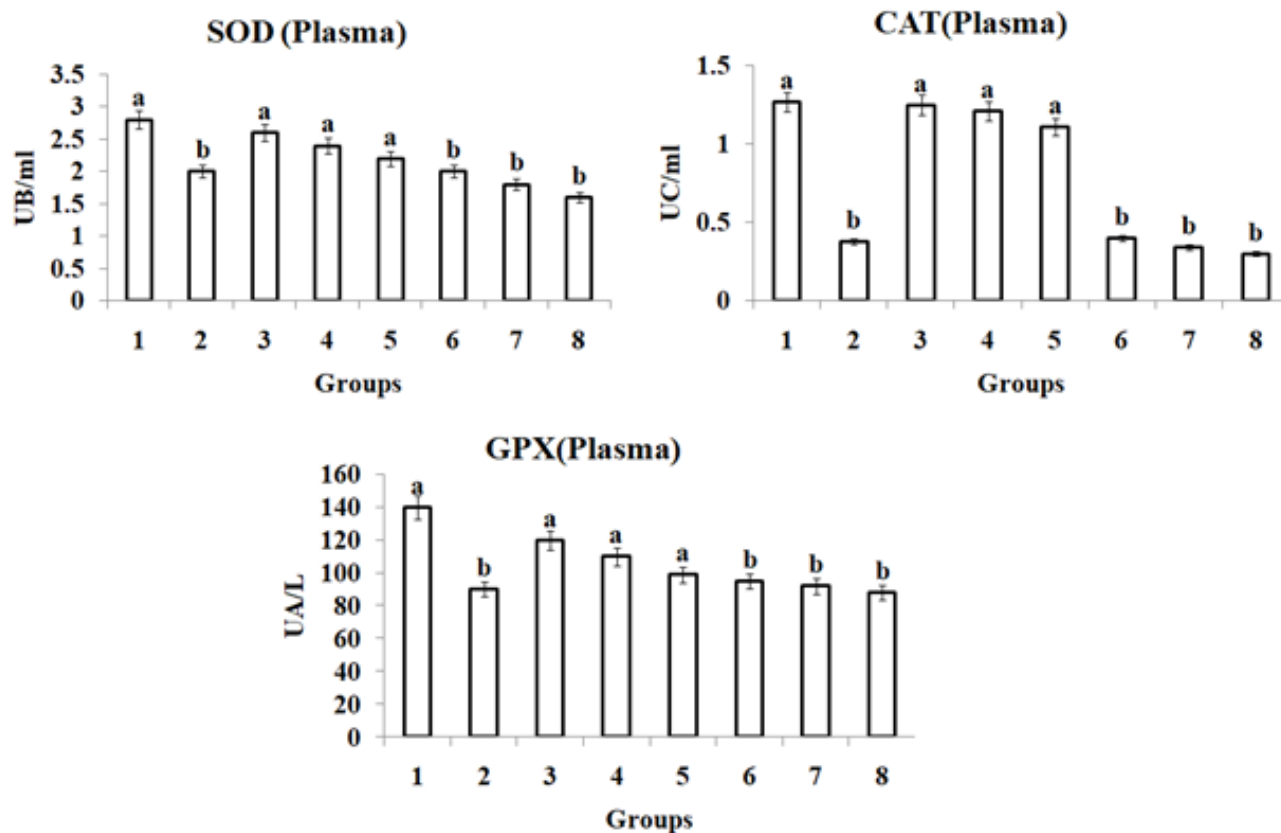
Groups/ Treatment	Control	DMBA	10% Sucrose	8% HFCS	25% HFCS	DMBA+10% Sucrose	DMBA + 8% HFCS	DMBA +25% HFCS
Keratosis	0	+++	0	0	+	+	+++	+++
Hyperplasia	0	+++	0	0	0	++	+++	+++
Dysplasia	0	+++	0	0	0	++	+++	+++
OSCC	0	+++	0	0	0	+++	+++	+++

- = No change, + = Mild, ++ = Moderate, +++ = Severe.

## DISCUSSION

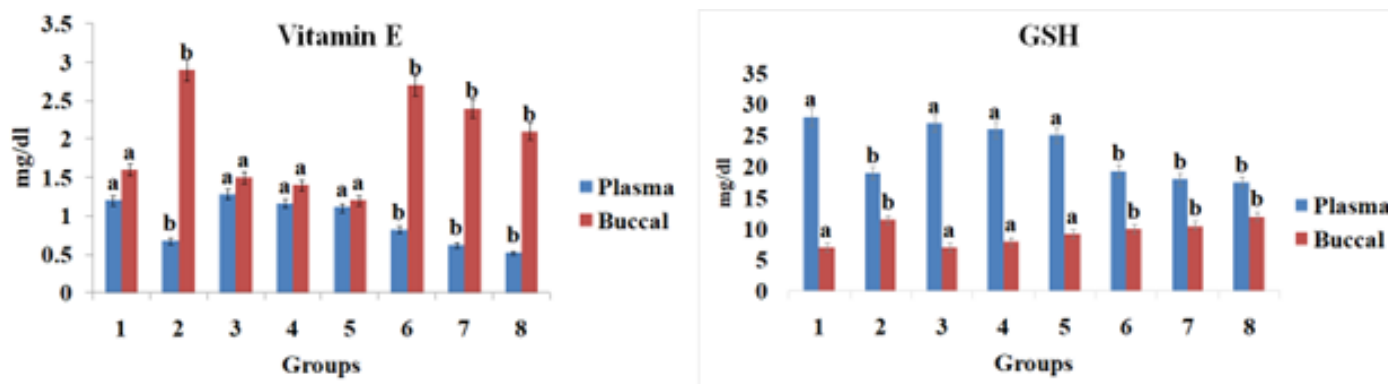
Hamsters possess a pocket like anatomical structure (buccal pouch) and used to examine the development and intervention of oral carcinoma by chemopreventive agents. Hamster buccal pouch carcinogenesis is an excellent model to study oral

carcinogenesis because the development of 7,12-dimethylbenz[a]anthracene (DMBA)-induced squamous cell carcinoma in hamster buccal pouch simulates many of the histological, biochemical, and molecular alterations that occur in human oral carcinoma. Since, hamster has been used as an experimental model to study the biochemical, molecular, or morphological



**Figure 6:** Shows the plasma levels of enzymatic antioxidants in the experimental and control groups of hamsters.

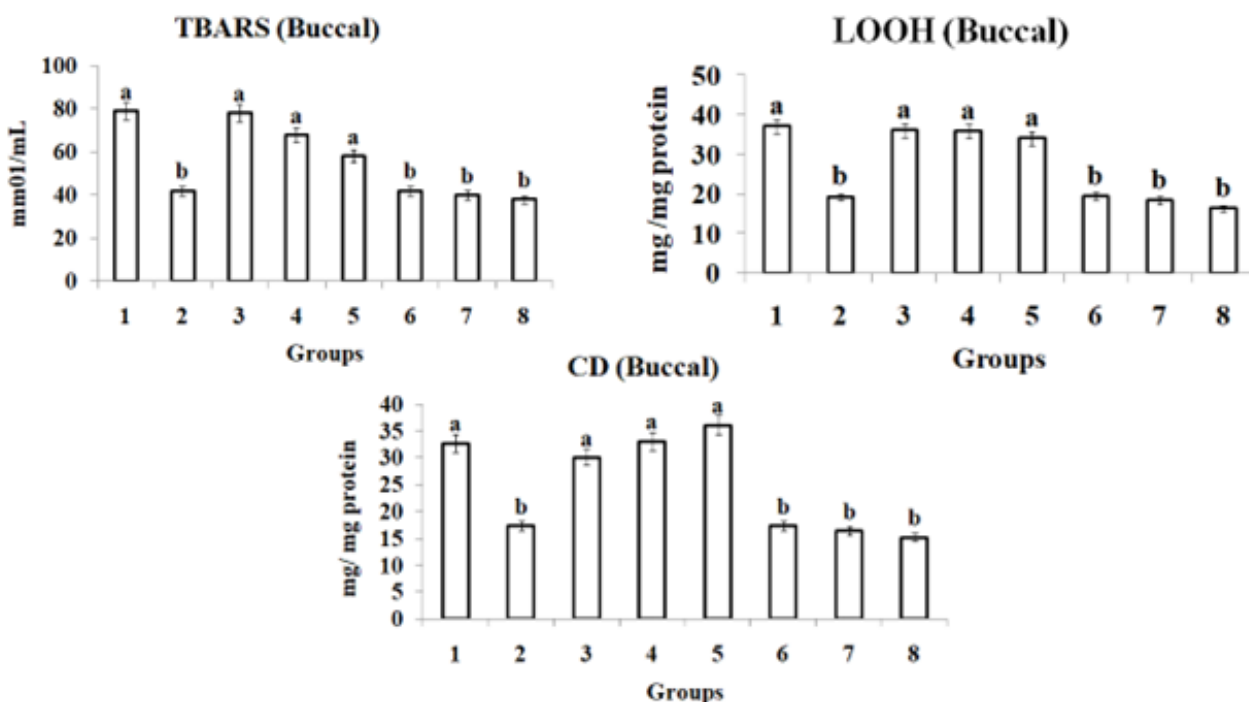
Bars are expressed as mean SD for 6 animals in each group. (a and b) Values that do not share a common superscript letter between groups different significance. a significantly different from group 6, 7 and 8; b significantly different from group 3, 4 and 5 (DMRT).



**Figure 7:** Shows the condition of the non-enzymatic antioxidants in plasma & buccal tissue in the experimental and control groups of hamsters.

The mean SD for the six animals in each group is given as bars. Values that do not belong to the same group as a common superscript letter have a different significance (a and b). Significant differences from groups 3, 4, and 5 and groups 6, 7, and 8 are shown in (DMRT).

A – Micromoles of glutathione utilized/min; B – The number of enzymes required to inhibit 50% Nitroblue-Tetrazolium (NBT) reduction; C – Micromoles of H<sub>2</sub>O<sub>2</sub> utilized/s.



**Figure 8:** Shows the current status of LPO (TBARS, CD, and LOOH) levels in the buccal mucosa of each group of experimental and control hamsters

The mean SD for the six animals in each group is given as bars. Values that do not belong to the same group as a common superscript letter have a different significance (a and b). Significant differences from groups 3, 4, and 5 and groups 6, 7, and 8 are shown in (DMRT).

A – Micromoles of glutathione utilized/min; B – The number of enzymes required to inhibit 50% Nitroblue-Tetrazolium (NBT) reduction; C – Micromoles of H<sub>2</sub>O<sub>2</sub> utilized/sec. Thiobarbuturic Acid Reactive Substances (TBARS).

**Table 3: Phase I and II enzyme activities and GSH levels in the livers of control and experimental hamsters.**

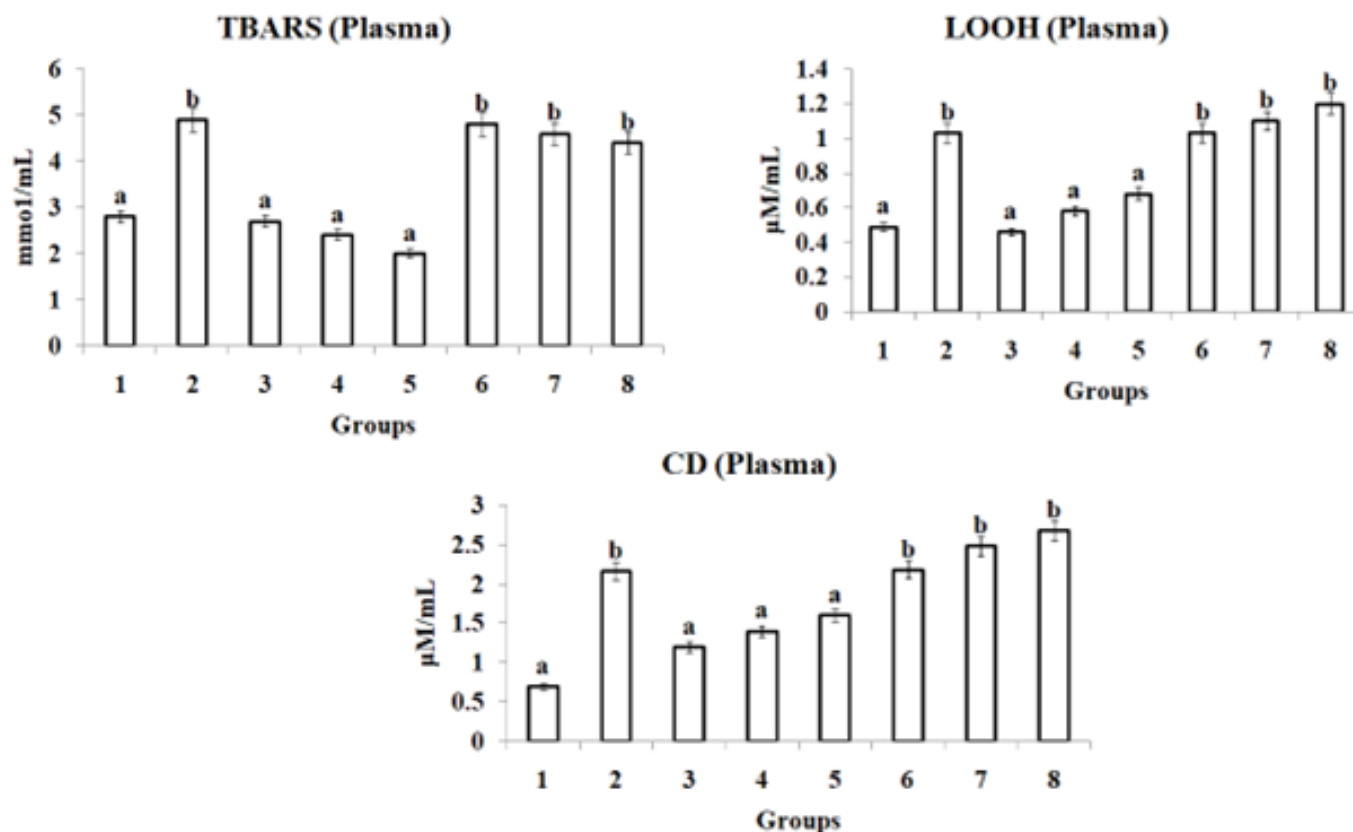
Parameters	Control	DMBA	10% Sucrose	8% HFCS	25% HFCS	DMBA+10% Sucrose	DMBA + 8% HFCS	DMBA +25% HFCS
Phase I								
Cyt P <sub>450</sub> (U <sup>X</sup> /mg protein)	0.98±0.09 <sup>a</sup>	3.89±0.35 <sup>b</sup>	1.02±0.35 <sup>a</sup>	0.97±0.13 <sup>a</sup>	0.95±0.14 <sup>a</sup>	3.68±0.09 <sup>b</sup>	3.92±0.09 <sup>b</sup>	4.03±0.09 <sup>b</sup>
Cyt b <sub>5</sub> (U <sup>Y</sup> /mg protein)	0.29±0.02 <sup>a</sup>	0.57±0.05 <sup>a</sup>	0.31±0.04 <sup>a</sup>	0.36±0.04 <sup>a</sup>	0.38±0.03 <sup>a</sup>	0.59±0.02 <sup>b</sup>	0.62±0.02 <sup>b</sup>	0.67±0.02 <sup>b</sup>
Phase II								
GSH (μg/mg tissue)	7.91±0.78 <sup>a</sup>	14.90±1.39 <sup>b</sup>	7.21±1.08 <sup>c</sup>	8.12±0.94 <sup>d</sup>	8.98±0.93 <sup>d</sup>	13.89±0.77 <sup>a</sup>	14.98±0.77 <sup>a</sup>	15.49±0.77 <sup>a</sup>
GST (U <sup>A</sup> /mg protein)	0.93±0.08 <sup>a</sup>	2.70±0.26 <sup>b</sup>	1.01±0.18 <sup>a</sup>	1.09±0.08 <sup>a</sup>	1.48±0.07 <sup>a</sup>	2.77±0.08 <sup>b</sup>	3.01±0.08 <sup>b</sup>	3.46±0.08 <sup>b</sup>
GR (U <sup>B</sup> /mg protein)	2.24±0.22 <sup>a</sup>	6.94±0.39 <sup>b</sup>	2.23±0.57 <sup>a</sup>	3.49±0.48 <sup>a</sup>	4.89±0.45 <sup>a</sup>	6.12±0.28 <sup>b</sup>	6.99±0.28 <sup>b</sup>	7.19±0.28 <sup>b</sup>

The mean SD for the six animals in each group is given as bars. Values that do not belong to the same group as a common superscript letter have a different significance (a and b). A substantial difference from groups 6, 7, and 8; b a significant difference from groups 3, 4, and 5 (DMRT; Duncan's Multiple Range Test). Per milligram of protein, a nanomole of CDNB-GSH conjugates is generated per minute. B Per milligram of protein, no moles of NADPH are oxidized every minute. C Per minute per mg of protein, micromoles of 2, 6-dichloroindophenol are decreased. cytochrome P450 X micromoles. Cytochrome b5 molecules, Y.

aspects of oral carcinogenesis.<sup>[9]</sup> Cancerous and non-cancerous oral tissues of hamsters, which were fed sugar and HFCS were assessed. The purpose of this study was to determine whether HFCS, at a dosage suitable for real-world consumption, can affect chemically-induced oral carcinogenesis in male hamsters as well

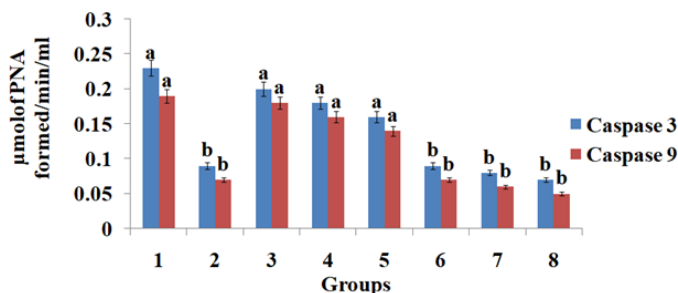
as its potential impact on apoptosis during this process. Oral squamous cell carcinoma was induced by DMBA.

7,12-Dimethylbenz[a] Anthracene (DMBA), a potent organ and site-specific carcinogen with immunosuppressive property, is widely used to induce Oral Squamous Cell Carcinoma (OSCC) in



**Figure 9:** Status of LPO (TBARS, CD and LOOH) levels in Plasma of control and experimental hamsters in each group.

The mean SD for the six animals in each group is given as bars. Values that do not belong to the same group as a common superscript letter have a different significance (a and b). Significant differences from groups 3, 4, and 5 and groups 6, 7, and 8 are shown in (DMRT).



**Figure 10:** Caspase 3 and 9 activity levels in the buccal mucosa of untreated control and experimental hamsters.

For each set of six animals, the bars are expressed as mean SD. Values that don't have a common superscript differ from one another significantly at p .05 (variance analysis followed by DMRT).

hamsters' buccal mucosa. DMBA manifests its carcinogenic effect in the target tissues through formation of DNA adducts, induction of chronic inflammation, over production of Reactive Oxygen Species (ROS), and oxidative DNA damage. DMBA-induced hamster buccal pouch carcinogenesis is a commonly employed and widely accepted model to investigate the chemopreventive potential of natural products since DMBA-induced cell surface abnormalities closely mimics that of human oral tumor.<sup>[7]</sup>

There is debate concerning the relationship between fructose consumption and cancer, and more research is needed in this area. According to a short-term study, sugar and HFCS consumption had the same effects.<sup>[31]</sup> Therefore, it is important to research the long-term clinical trials linking fructose consumption to a range of cancer risks.<sup>[32]</sup> In postmenopausal Danish women between 1993 and 1997, Nielsen *et al.*<sup>[33]</sup> observed no correlation between fructose intake and either estrogen-dependent or estrogen-independent breast cancer. According to Holmes *et al.*,<sup>[34]</sup> there is no link between dietary carbohydrate intake and breast cancer in women between the ages of 34 and 59. Sucrose intake did not appear to raise the risk of pancreatic cancer in a cohort study,<sup>[35]</sup> while fructose intake. The purpose of the current investigation was to test our hypothesis regarding the additive effects of HFCS in a model of hamster cheek pouch carcinogenesis caused by 7,12-Dimethylbenz(a)Anthracene (DMBA). Tumor morphology, buccal histopathology, and biochemical markers such as DMBA-induced oral carcinogenesis: lipid peroxidation by-products, status of enzymatic and non-enzymatic antioxidants, levels of phase I and phase II detoxification agents, and excretion of carcinogenic metabolite.

Fructose consumption has increased recently, and processed foods and beverages contain HFCS, a commercial sugar ingredient,



because of its potent sweetening power and low cost.<sup>[36]</sup> A decline in physical activity and an increase in body weight are significant risk factors for a number of diseases. Fructose consumption may contribute to metabolic syndrome and obesity.<sup>[37]</sup> According to Goncalves *et al.*, mice given HFCS showed a marked rise in tumor size and grade even in the absence of obesity and the metabolic syndrome. Fructose and glucose concentrations in the intestinal lumen and serum were both enhanced by HFCS, and tumors transported both sugars due to greater expression of the transporter proteins GLUT 2 and GLUT 5.<sup>[38]</sup>

The impact of HFCS on body weight is unclear and up for debate. The various researches on how fructose or sweeteners containing fructose affects weight gain have been on the radar for a time. The effects on body weight were altered by altering the fructose intake and research duration.<sup>[39]</sup> According to Rizkalla, male Wistar rats were fed 15% fructose or cornstarch as energy for 15 months, and body weight changes were not statistically significant.<sup>[40]</sup> After two weeks of feeding 60% fructose to golden Syrian hamsters, obesity and subsequent weight gain were observed.<sup>[41]</sup> Studies on males, females, and middle-aged males have shown that body weight rose as a result of varying food amounts and study duration.<sup>[42]</sup> According to Vědra *et al.*<sup>[40]</sup> persons who are fat or overweight do not experience any physical changes as a result of consuming fructose at typical levels. In terms of anthropometric, insulin, high-density lipoprotein cholesterol (HDL-C), triglycerides (TG), and total cholesterol measures, Stanhope *et al.*<sup>[43]</sup> found no differences between the glucose, fructose, and HFCS groups. According to Forshee *et al.*,<sup>[44]</sup> the differences in weight gain between HFCS and sucrose and ecological studies linked to HFCS use are unclear. Bocarsly<sup>[45]</sup> stated that male rats with 12 hr of 8% HFCS feeding had more body weight than sucrose feeding groups in 2 months, and no difference was discovered in blood glucose levels between groups and animals with *ad libitum* HFCS were seen. Our volume of food and duration of study were different from theirs greater body weight, belly fat, and TG in comparison to the chow group after 6 or 7 months. In the current study, hamsters who consumed DMBA alone had lower body weights than hamsters in groups 3, 4, and 5, however hamsters that consumed HFCS at various levels of 10% sucrose, 8%, and 25%/kg b.w. had heavier bodies. When compared to the control group, hamsters receiving water containing 10% sucrose, 8%, and 25%/kg b.w. showed significant increases in body weight. Our results corroborated to earlier reports.

Fructose serves as a fuel for cancer cells and stimulates cancer growth. Definitely other dietary components or lifestyle factors could contribute to cancer development. According to Port AM,<sup>[46]</sup> fructose is used by cancer cells for proliferating and making nucleic acids, and eating high fructose foods can accelerate the growth of cancer by altering cellular metabolism and causing DNA damage, inflammation, and reactive oxygen species. According to O'Byrne and Dalgleish,<sup>[47]</sup> angiogenesis and inflammatory mediators

are upregulated during the inflammatory phase, creating the ideal conditions for the growth of malignancy. Consuming excessive fructose and HFCS contributes to the development of cancer by encouraging the expression of inflammatory cells.<sup>[48]</sup> According to the current study's histological findings, hamsters exposed to DMBA alone and HFCS (8% and 25%) with DMBA developed significant keratosis, hyperplasia, dysplasia, and well-differentiated squamous cell carcinoma in their buccal pouches. Malignant tumors and the keratin pearl are also seen as signs of well-differentiated Squamous Cell Carcinoma (SCC). Hamsters given 25% HFCS had hyperkeratosis and hyperplasia with mitotic alterations, which were associated with earlier observations.

Consuming fructose could influence how pancreatic cancer cells proliferate and behave.<sup>[8]</sup> In another study<sup>[49]</sup> male Sprague Dawley rats received either water and food or fructose in the drinking water (120 g/L) and were exposed to the carcinogen N-nitrosomorpholine (NNM) for 7 weeks. The fructose group with NNM had a 46% incidence of hepatocellular carcinoma compared to 24% in the NNM alone group, and there was no difference in the incidences of other malignancies between the groups. In the current study after 8 weeks feeding period, hamsters painted with DMBA (0.5%) plus HFCS groups were observed oral squamous cell carcinoma and comparable cancers in all DMBA groups that have been administered were observed after 10<sup>th</sup> week only. From this HFCS triggering effect on the tumour development very promptly were confirmed.

Numbers of tumours were also increased in HFCS plus DMBA groups and no tumours were found in sucrose and HFCS alone groups. Even less information is available regarding the precise impact of HFCS on oral cancer; there are actually no published statistics. According to Wang *et al.* 2022,<sup>[50]</sup> HFCS stimulates the production of proinflammatory cytokines in RAW264.7 macrophages through nuclear factor-B (NF-B) signaling mediated by Reactive Oxygen Species (ROS). Additionally, the ROS scavenger N-acetylcysteine (NAC) suppresses the ROS-mediated NF-B signaling pathway in RAW264.7 macrophages and treats animals with HFCS-aggravated colitis. We examined the LOOH, TBARS, and CD in plasma and buccal tissues for the current investigation.

Estimating the plasma TBARS level is thought to be a trustworthy signal for determining the severity of tissue damage. Oral cavity malignancies are the most common places where low amounts of TBARS have been detected. Previous research conducted in our lab showed that the circulation of rats with tumors included higher levels of TBARS. Therefore, increased plasma TBARS levels may be the result of excessive synthesis and diffusion from injured tissues that then leak into the plasma.<sup>[51]</sup> In the current study HFCS might be increased the oral mucosa's vulnerability to lipid peroxidation, suggesting that HFCS has a stimulatory effect on cell proliferation in the target area.

Cells may develop structural and functional defects as a result of free radical-mediated oxidative stress, rendering them vulnerable and defenseless.<sup>[52]</sup> Reduced levels of non-enzymatic antioxidants in the plasma of tumor-bearing animals imply that malignant tumors use these antioxidants to meet their nutritional needs as they grow or to counteract the harmful effects of ROS in the circulatory system. Enzymatic antioxidants' decreased activity is likely caused by their depletion from controlling the high levels of circulating lipid peroxidation by products.<sup>[53]</sup> HFCS groups realized the lower level of antioxidants marker SOD, CAT and GPx expressions were observed in plasma and buccal tissues. Even effect of HFCS alone was higher expressions observed than the control hamster; it indicates that HFCS induced toxicity at 25% dose administered by water *ad libitum*. Toxic effects of HFCS were proved by increase LPO, inhibition of antioxidants and cell death suppression process and induction of cell proliferation were confirmed in DMBA induced hamsters. Phase II enzymes are involved in the detoxification of carcinogenic chemicals, whereas phase I biotransformation enzymes are involved in the metabolic activation of carcinogens. According to studies, DMBA-induced oral carcinogenesis considerably changed the activity of phase I and phase II enzymes.<sup>[54]</sup> The liver of hamsters given DMBA treatment showed increased phase I enzyme activity and decreased phase II enzyme activity, indicating that the ultimate carcinogenic metabolite of DMBA, dihydrodiolepoxide, was deposited and not eliminated during DMBA-induced oral carcinogenesis. Given that glutathione is essential for the detoxification of cancer-causing compounds and the scavenging of ROS, the decreased activity of GST and GR in the liver of DMBA-treated hamsters is most likely caused by the reduced availability of this enzyme's substrate.

Given that glutathione is essential for the detoxification of cancer-causing compounds and the scavenging of ROS, the decreased activity of GST and GR in the liver of DMBA-treated hamsters is most likely caused by the reduced availability of this enzyme's substrate. Phase I and phase II enzyme status was altered in the liver and buccal mucosa of hamsters given DMBA treatment, suggesting that HFCS may have played a significant role in the carcinogens' toxic effects by either promoting the development of DMBA's metabolic activation or delaying the excretion of the carcinogenic metabolite.

Savran *et al.* 2019 investigated Melatonin (MLT)'s protective effects in Sprague-Dawley rats against HFCS-induced endothelial and cardiac dysfunction through oxidative stress and inflammation.<sup>[55]</sup> Then they explained the caspase 3 expressions were suppressed in HFCS induced rats. Similarly, the apoptotic markers enzyme caspase-3 and caspase-9 expressions were reduced in DMBA and HFCS+DMBA exposed hamsters. The

status of the aforementioned markers was noticeably shifted opposite to the usual range especially HFCS 25% concentration showed lower expression of caspase 3 and 9. It indicates the effects of HFCS on hamsters.

Excess consumption of fructose in additives like table sugar or High-Fructose Corn Syrup (HFCS) not only contributes to obesity, but it may increase Colorectal Cancer (CRC) cell survival, leading to larger tumors and increased symptom burden in patients at higher risk, researchers showed in study results published in Nature.<sup>[56]</sup> In the overall hypothesis of the current study we analysed HFCS with DMBA gives more effect in tumour development, suppressed antioxidant enzymes, increased lipid peroxidation, and suppressed the expression of caspase 3 and caspase 9 in experimental hamster's dose dependently. And also, histological pattern were totally disaggregated pattern of oral tissues arrangements showed transformed tissue cells, keratin pearls, hyperplasia, dysplasia, and in situ carcinoma development higher in HFCS with DMBA.

## CONCLUSION

This study showed how HFCS affected DMBA-induced hamster buccal pouch carcinogenesis and came to the conclusion that HFCS may trigger the early stages of oral carcinogenesis. The additive potential of HFCS is probably by meeting nutrient demands of growing tumors or to its inhibition of antioxidant potential and modulating effect on the toxic cascade during DMBA-induced oral carcinogenesis. To further validate the effect of HFCS, this study is extended to investigate the effect of HFCS on the expression of different molecular markers linked to the development of oral cancer.

## ACKNOWLEDGEMENT

We thank Er GM, Srinivasan, Managing Director, Galileovasan Offshore and Research and Development Private Limited or his unconditional support to carry out experiment by providing timely requirements and guidance during the study. Authors also like to thank Dr. A. Vijayalakshmi for assist the experimental work in providing for their support.

## ETHICS APPROVAL AND CONSENT TO PARTICIPATE

The animal treatment and protocol employed was approved by the Committee for the Purpose of Control and Supervision of Experiments on Animals (CPCSEA-Proposal no IAEC/K. KAVITHA/AU/PhD/KMCP/161/2022-23), Ministry of Environment, Forests and Climate Change, Government of India, provided the guidelines for all animal quarantine and experimental procedures.

## ABBREVIATIONS

**CD:** Conjugated Dienes; **LOOH:** Lipid peroxidation; **TBARS:** Thiobarbituric Acid; **SOD:** Superoxide Dismutase; **CAT:** Catalase; **GPx:** Glutathione Peroxides; **GR:** Glutathione Reductase; **GST:** Glutathione.

## CONFLICT OF INTEREST

The authors declare that there is no conflict of interest.

## SUMMARY

We summarised from the current study to the main hypothesis, HFCS combined with DMBA has a greater impact on the growth of tumors, inhibits antioxidant enzymes, increases lipid peroxidation, and suppresses caspase 3 and caspase 9 expression in experimental hamsters in a dose-dependent manner. *In situ* carcinoma development was increased in HFCS with DMBA, and the histological pattern of the oral tissue's arrangements revealed altered tissue cells, keratin pearls, hyperplasia, dysplasia, and hyperplasia. Main impact of HFCS on DMBA-induced HBPCs, may initiate the early stages of oral carcinogenesis. The dietary requirements of developing tumors are likely met by HFCS, which also has the additional potential of inhibiting antioxidant capability and modifying the harmful cascade during DMBA-induced oral carcinogenesis. This study is expanded to look at how HFCS affects the expression of various molecular markers connected to the emergence of oral cancer in order to further validate the effect of HFCS.

## REFERENCES

- Sankaranarayanan R, Ramadas K, Amarasinghe H, Sujha S, Newell. Oral cancer: prevention, early detection, and treatment. Cancer: disease control priorities. Washington, (DC): International Bank for Reconstruction and Development / The World Bank. 2015;3.
- Geum DH, Roh YC, Yoon SY, Kim HG, Lee JH, Song JM, *et al.* The impact factors on 5-year survival rate in patients operated with oral cancer. *J Korean Assoc Oral Maxillofac Surg.* 2013;39(5):207-16. doi: 10.5125/jkaoms.2013.39.5.207, PMID 24471047.
- Ginsburg O, Yip CH, Brooks A, Cabanes A, Caleffi M, Dunstan Yataco JA, *et al.* Breast cancer early detection: A phased approach to implementation. *Cancer.* 2020;126:Suppl 10: 2379-93. doi: 10.1002/cncr.32887, PMID 32348566.
- Shahoumi LA. Oral cancer stem cells: therapeutic implications and challenges. *Front Oral Health.* 2021;2:685236. doi: 10.3389/froh.2021.685236, PMID 35048028.
- Vigneswaran N, Williams MD. Epidemiologic trends in head and neck cancer and aids in diagnosis. *Oral Maxillofac Surg Clin North Am.* 2014;26(2):123-41. doi: 10.1016/j.coms.2014.01.001, PMID 24794262.
- Johnson DE, Burtness B, Leemans CR, Lui VWY, Bauman JE, Grandis JR. Head and neck squamous cell carcinoma. *Nat Rev Dis Primers.* 2020;6(1):92. doi: 10.1038/s41572-020-00224-3, PMID 33243986.
- Liu Z, Kundu-Roy T, Matsuura I, Wang G, Lin Y, Lou YR, *et al.* Carcinogen 7,12-dimethylbenz[a] anthracene-induced mammary tumorigenesis is accelerated in Smad3 heterozygous mice compared to Smad3 wild type mice. *Oncotarget.* 2016;7(40):64878-85. doi: 10.18632/oncotarget.11713, PMID 27588495.
- Martínez B DA, Barato Gómez PA, Iregui Castro CA, Rosas Pérez JE. DMBA-induced oral carcinoma in Syrian hamster: increased carcinogenic effect by dexamethasone Coexposition. *BioMed Res Int.* 2020; 2020:1470868. doi: 10.1155/2020/1470868, PMID 32149076.
- Yapikakis C, Kalogera S, Papakosta V, Vassiliou S. The hamster model of sequential oral carcinogenesis: an update. *In vivo.* 2019;33(6):1751-5. doi: 10.21873/invivo.11665, PMID 31662499.
- Rizkalla SW. Health implications of fructose consumption: a review of recent data. *Nutr Metab (Lond).* 2010;7(7):82. doi: 10.1186/1743-7075-7-82, PMID 21050460.
- Taskinen MR, Packard CJ, Borén J. Dietary fructose and the metabolic syndrome. *Nutrients.* 2019;11(9):1987. doi: 10.3390/nu11091987, PMID 31443567.
- Baba AI, Cătoi C. Comparative oncology. *Carcinogenesis.* 2007;2.
- Enzmann H, Dettler T, Ohlhauser D, Stumpf H, Bannasch P. Dietary fructose enhances the development of atypical acinar cell nodules in the pancreas of rats pretreated with N-nitrosomorpholine. *Arch Geschwulstforsch.* 1990;60(4):283-7. PMID 2390005.
- Hsieh CC, Shyr YM, Liao WY, Chen TH, Wang SE, Lu PC, *et al.* Elevation of  $\beta$ -galactosidase  $\alpha$ 2,6-sialyltransferase 1 in a fructoseresponsive manner promotes pancreatic cancer metastasis. *Oncotarget.* 2017;8(5):7691-709. doi: 10.18632/oncotarget.13845, PMID 28032597.
- White JS, Hobbs LJ, Fernandez S. Fructose content and composition of commercial HFCS-sweetened carbonated beverages. *Int J Obes (Lond).* 2015;39(1):176-82. doi: 10.1038/ijo.2014.73. PMID 24798032, PMCID PMC4285619.
- Mai BH, Yan LJ. The negative and detrimental effects of high fructose on the liver, with special reference to metabolic disorders. *Diabetes Metab Syndr Obes.* 2019;12:821-6. doi: 10.2147/DMSO.S198968, PMID 31213868.
- Abdelmalek MF, Suzuki A, Guy C, Unalp-Arida A, Colvin R, Johnson RJ, *et al.* Increased fructose consumption is associated with fibrosis severity in patients with nonalcoholic fatty liver disease. *Hepatology.* 2010;51(6):1961-71. doi: 10.1002/hep.23535, PMID 20301112.
- Liu H, Heaney AP. Refined fructose and cancer. *Expert Opin Ther Targets.* 2011;15(9):1049-59. doi: 10.1517/14728222.2011.588208, PMID 21623683.
- Coussens LM, Werb Z. Inflammation and cancer. *Nature.* 2002;420(6917):860-7. doi: 10.1038/nature01322, PMID 12490959, PMCID PMC2803035.
- Lowry OH, Rosebrough NJ, Farr AL, Randall RJ. Protein measurement with the Folin phenol reagent. *J Biol Chem.* 1951;193(1):265-75. doi: 10.1016/S0021-9258(19)52451-6, PMID 14907713.
- Yagi K. Lipid peroxides and human diseases. *Chem Phys Lipids.* 1987;45(2-4):337-51. doi: 10.1016/0009-3084(87)90071-5, PMID 3319232.
- Ohkawa H, Ohishi N, Yagi K. Assay for lipid peroxides in animal tissues by thiobarbituric acid reaction. *Anal Biochem.* 1979;95(2):351-8. doi: 10.1016/0003-2697(79)90738-3, PMID 36810.
- Kakkar P, Das BP, Viswanathan PN. A modified spectrophotometric assay of superoxide dismutase. *Indian J Biochem Biophys.* 1984;21(2):130-2. PMID 6490072.
- Rotruck JT, Pope AL, Ganther HE, Swanson AB, Hafeman DG, Hoekstra WG. Selenium: biochemical role as a component of glutathione peroxidase. *Science.* 1973;179(4073):588-90. doi: 10.1126/science.179.4073.588, PMID 4686466.
- Sinha AK. Colorimetric assay of catalase. *Anal Biochem.* 1972;47(2):389-94. doi: 10.1016/0003-2697(72)90132-7, PMID 4556490.
- Palan PR, Mikhail MS, Basu J, Romney SL. Plasma levels of antioxidant beta-carotene and alpha-tocopherol in uterine cervix dysplasias and cancer. *Nutr Cancer.* 1991;15(1):13-20. doi: 10.1080/01635589109514106, PMID 2017395.
- Beutler E, Kelly BM. The effect of sodium nitrite on red cell GSH. *Experientia.* 1963;19(2):96-7. doi: 10.1007/BF02148042, PMID 13967892.
- Tietze F. Enzymic method for quantitative determination of nanogram amounts of total and oxidized glutathione: applications to mammalian blood and other tissues. *Anal Biochem.* 1969;27(3):502-22. doi: 10.1016/0003-2697(69)90064-5, PMID 4388022.
- Desai ID. Vitamin E analysis methods for animal tissues. *Methods Enzymol.* 1984;105:138-47. doi: 10.1016/s0076-6879(84)05019-9, PMID 6727662.
- Omura T, Sato R. The carbon monoxide-binding pigment of liver microsomes. I. Evidence for its hemoprotein nature. *J Biol Chem.* 1964;239(7):2370-8. doi: 10.1016/S0021-9258(20)82244-3, PMID 14209971.
- Dewdney B, Roberts A, Qiao L, George J, Hebbard L. A sweet connection? Fructose's role in hepatocellular carcinoma. *Biomolecules.* 2020;10(4):496. doi: 10.3390/biom10040496, PMID 32218179.
- Nakagawa T, Lanasp MA, Millan IS, Fini M, Rivard CJ, Sanchez-Lozada LG, *et al.* Fructose contributes to the Warburg effect for cancer growth. *Cancer Metab.* 2020;8(1):16. doi: 10.1186/s40170-020-00222-9, PMID 32670573.
- Nielsen TG, Olsen A, Christensen J, Overvad K, Tjønneland A. Dietary carbohydrate intake is not associated with the breast cancer incidence rate ratio in postmenopausal Danish women. *J Nutr.* 2005;135(1):124-8. doi: 10.1093/jn/135.1.124, PMID 15623843.
- Holmes MD, Liu S, Hankinson SE, Colditz GA, Hunter DJ, Willett WC. Dietary carbohydrates, fiber, and breast cancer risk. *Am J Epidemiol.* 2004;159(8):732-9. doi: 10.1093/aje/kwh112, PMID 15051582.
- Simon MS, Shikany JM, Neuhauser ML, Rohan T, Nirmal K, Cui Y, *et al.* Women's Health Initiative. Glycemic index, glycemic load, and the risk of pancreatic cancer among postmenopausal women in the women's health initiative observational study and clinical trial. *Cancer Causes Control.* 2010;21(12):2129-36. doi: 10.1007/s10552-010-9632-4, PMID 20711806.
- Lowette K, Roosen L, Tack J, Vanden Berghe P. Effects of high-fructose diets on central appetite signaling and cognitive function. *Front Nutr.* 2015;2:5. doi: 10.3389/fnut.2015.00005, PMID 25988134.
- Pereira RM, Botezelli JD, da Cruz Rodrigues KC, Mekary RA, Cintra DE, Pauli JR, *et al.* Fructose consumption in the development of obesity and the effects of different protocols of physical exercise on the hepatic metabolism. *Nutrients.* 2017; 9(4): 405. doi: 10.3390/nu9040405, PMID 28425939.

38. Goncalves MD, Lu C, Tutnauer J, Hartman TE, Hwang SK, Murphy CJ, *et al.* High-fructose corn syrup enhances intestinal tumor growth in mice. *Science*; 22363. 2019;363(6433):366433. doi: 10.1126/science.aat8515, PMID 30898933.
39. Malik VS, Hu FB. Fructose and cardiometabolic health: what the evidence from sugar-sweetened beverages tells us. *J Am Coll Cardiol*. 2015;66(14):1615-24. doi: 10.1016/j.jacc.2015.08.025, PMID 26429086.
40. Horne RG, Yu Y, Zhang R, Abdalqadir N, Rossi L, Surette M, *et al.* High fat-high fructose diet-induced changes in the gut microbiota associated with dyslipidemia in Syrian hamsters. *Nutrients*. 2020;12(11):3557. doi: 10.3390/nu12113557, PMID 33233570, PMCID PMC7699731.
41. Zhang L, Perdomo G, Kim DH, Qu S, Ringquist S, Trucco M, *et al.* Proteomic analysis of fructose-induced fatty liver in hamsters. *Metabolism*. 2008;57(8):1115-24. doi: 10.1016/j.metabol.2008.03.017, PMID 18640390.
42. Vadera BN, Yadav SB, Yadav BS, Parmar DV, Unadkat SV. Study on obesity and influence of dietary factors on the weight status of an adult population in Jamnagar city of Gujarat: a cross-sectional analytical study. *Indian J Community Med*. 2010;35(4):482-6. doi: 10.4103/0970-0218.74346, PMID 21278866, PMCID PMC3026124.
43. Stanhope KL, Medici V, Bremer AA, Lee V, Lam HD, Nunez MV, *et al.* A dose-response study of consuming high-fructose corn syrup-sweetened beverages on lipid/lipoprotein risk factors for cardiovascular disease in young adults. *Am J Clin Nutr*. 2015;101(6):1144-54. doi: 10.3945/ajcn.114.100461, PMID 25904601.
44. Forshee RA, Storey ML, Allison DB, Glinsmann WH, Hein GL, Lineback DR, *et al.* A critical examination of the evidence relating high fructose corn syrup and weight gain. *Crit Rev Food Sci Nutr*. 2007;47(6):561-82. doi: 10.1080/10408390600846457, PMID 17653981.
45. Bocarsly ME, Powell ES, Avena NM, Hoebel BG. High-fructose corn syrup causes characteristics of obesity in rats: increased body weight, body fat and triglyceride levels. *Pharmacol Biochem Behav*. 2010;97(1):101-6. doi: 10.1016/j.pbb.2010.02.012, PMID 20219526.
46. Port AM, Ruth MR, Istfan NW. Fructose consumption and cancer: is there a connection? *Curr Opin Endocrinol Diabetes Obes*. 2012;19(5):367-74. doi: 10.1097/MED.0b013e328357f0cb, PMID 22922366.
47. Aguilar-Cazares D, Chavez-Dominguez R, Carlos-Reyes A, Lopez-Camarillo C, Hernandez de la Cruz ON, Lopez-Gonzalez JS. Contribution of angiogenesis to inflammation and cancer. *Front Oncol*. 2019;129(9):1399. doi: 10.3389/fonc.2019.01399, PMID 31921656.
48. Krause N, Wegner A. Fructose metabolism in cancer. *Cells*. 2020;89(912):2635. doi: 10.3390/cells9122635, PMID 33302403.
49. Romualdo GR, Leroy K, Costa CJS, Prata GB, Vanderborght B, da Silva TC, *et al.* *In vivo* and *in vitro* models of hepatocellular carcinoma: current strategies for translational modeling. *Cancers (Basel)*. 2021;13(21):5583. doi: 10.3390/cancers13215583, PMID 34771745.
50. Wang L, Ji T, Yuan Y, Fu H, Wang Y, Tian S, *et al.* High-fructose corn syrup promotes proinflammatory Macrophage activation via ROS-mediated NF- $\kappa$ B signaling and exacerbates colitis in mice. *Int Immunopharmacol*. 2022;109:108814. doi: 10.1016/j.intimp.2022.108814, PMID 35533555.
51. Slopovsky J, Kucharska J, Obertova J, Mego M, Kalavska K, Cingelova S, *et al.* Plasma thiobarbituric acid reactive substances predicts survival in chemotherapy naïve patients with metastatic urothelial carcinoma. *Transl Oncol*. 2021;14(1):100890. doi: 10.1016/j.tranon.2020.100890, PMID 33059122.
52. Narendhirakannan RT, Hannah MA. Oxidative stress and skin cancer: an overview. *Indian J Clin Biochem*. 2013;28(2):110-5. doi: 10.1007/s12291-012-0278-8, PMID 24426195.
53. Kurutas EB. The importance of antioxidants which play the role in cellular response against oxidative/nitrosative stress: current state. *Nutr J*. 2016;15(1):71. doi: 10.1186/s12937-016-0186-5, PMID 27456681.
54. Hodges RE, Minich DM. Modulation of metabolic detoxification pathways using foods and food-derived components: A scientific review with clinical application. *J Nutr Metab*. 2015; 2015:760689. doi: 10.1155/2015/760689, PMID 26167297.
55. Savran M, Asci H, Ozmen O, Erzurumlu Y, Savas HB, Sonmez Y, *et al.* Melatonin protects the heart and endothelium against high fructose corn syrup consumption-induced cardiovascular toxicity via SIRT-1 signaling. *Hum Exp Toxicol*. 2019;38(10):1212-23. doi: 10.1177/0960327119860188, PMID 31256681.
56. Taylor SR, Ramsamooj S, Liang RJ, Katti A, Pozovskiy R, Vasan N, *et al.* Dietary fructose improves intestinal cell survival and nutrient absorption. *Nature*. 2021;597(7875):263-7. doi: 10.1038/s41586-021-03827-2, PMID 34408323.

**Cite this article:** Kalimuthu K, Ganapathy S, Elumalai B, Thayammal AKR, Veeravarmal V, Annamalai V. Additive Effects of High Fructose Corn Syrup (HFCS) in Experimental Oral Carcinogenesis. *Pharmacog Res*. 2023;15(4):819-30.